Case report

Med Lasers 2025;14(3):181-184
https://doi.org/10.25289/ML.25.014
pISSN 2287-8300 · eISSN 2288-0224

MEDICAL LASERS
Engineering Basic Research and Clinical Application

Case report

Successful treatment of solar lentigines using a novel 532-nm nanosecond neodymium-doped yttrium aluminum garnet vasculature salvage laser surgery system: case series

Ngoc Ha Nguyen[1,2], Jeanne Jung[3], Sang Ju Lee[3], Young In Lee[1,4]

[1]*Department of Dermatology, Cutaneous Biology Research Institute, Yonsei University College of Medicine, Seoul, Republic of Korea*
[2]*Department of Dermatology, University of Medicine and Pharmacy at Ho Chi Minh City, Ho Chi Minh City, Vietnam*
[3]*Yonsei Star Skin & Laser Clinic, Seoul, Republic of Korea*
[4]*Scar Laser and Plastic Surgery Center, Yonsei Cancer Hospital, Seoul, Republic of Korea*

Solar lentigines are benign pigmented lesions commonly treated with 532-nm Q-switched neodymium-doped yttrium aluminum garnet (Nd:YAG) lasers, though outcomes can be limited by post-inflammatory hyperpigmentation (PIH), especially in darker skin types. This case series evaluated a novel 532-nm nanosecond Nd:YAG vasculature salvage laser surgery (VSLS) system, designed to minimize PIH risk through two key features: cryo-photothermolysis, which induces vasoconstriction to reduce hemoglobin absorption, and AutoDerm®, which enables precise lesion targeting. Two female patients in their 60s with persistent solar lentigines, unresponsive to prior laser treatments, underwent a single VSLS session. Complete resolution of the lentigines was achieved after one treatment session, with no signs of PIH, prolonged erythema, or scarring observed throughout 3 months of follow-up. This outcome suggests the VSLS system may offer a safer and more effective alternative for treating solar lentigines, particularly in patients at a higher risk of laser-induced complications.

Key words: Lentigo; Neodymium-doped yttrium aluminum garnet; Laser therapy; Laser surgery; Post-inflammatory hyperpigmentation

INTRODUCTION

Solar lentigines are common, small, hyperpigmented macules and/or patches typically found on sun-exposed areas of the skin, resulting from chronic sun exposure, such as the face [1]. While benign, lentigines can be a significant cosmetic concern for many individuals, prompting them to seek treatment. Various treatment modalities exist for lentigines, including topical agents, chemical peels, and light-based therapies [2,3]. Among the most frequently used are pigment-targeting lasers, such as the Q-switched (QS) 532-nm neodymium-doped yttrium aluminum garnet (Nd:YAG), often chosen due to the high absorption of its wavelength by melanin [4,5]. Despite their efficacy, QS lasers carry a risk of side effects, such as prolonged erythema and post-inflammatory hyperpigmentation (PIH), particularly for individuals with darker skin phototypes and Asian populations [6,7].

Recently, the vasculature salvage laser surgery (VSLS) system, utilizing a 532-nm nanosecond Nd:YAG laser, has been introduced as a novel approach designed to overcome some limitations of conventional lasers [8,9].

Received June 13, 2025, **Accepted** August 13, 2025

Correspondence
Young In Lee
E-mail: YLEE1124@yuhs.ac
ORCID: https://orcid.org/0000-0001-6831-7379

© Korean Society for Laser Medicine and Surgery
This is an open access article distributed under the terms of the Creative Commons Attribution Non-Commercial License (https://creativecommons.org/licenses/by-nc/4.0) which permits unrestricted non-commercial use, distribution, and reproduction in any medium, provided the original work is properly cited.

The VSLS system incorporates two key technologies. Firstly, a contact cooling system (cryo-photothermolysis [CPTL]) applies precision-controlled hyper-cooling (e.g., –2°C to –6°C) to the skin surface to induce temporary vasoconstriction in the papillary dermis, minimizing blood flow and reducing the absorption of laser energy by hemoglobin, a competing chromophore at 532 nm [8,9]. Secondly, an automatic lesion recognition technology (AutoDerm®) that scans the treatment area, identifies the lesion's shape and location, and delivers multiple rapid laser shots precisely and uniformly only to the target area, avoiding damage from prolonged cold exposure or irradiation of healthy skin [8,9]. The VSLS technique aims to deliver high-powered energy effectively to the target, inducing shock waves that cause mechanical separation of the epidermal lesion from the dermis while preserving the underlying vasculature [8,9].

This case series study describes the successful clearance of refractory solar lentigines with a single 532-nm nanosecond Nd:YAG VSLS system session.

A written informed consent was obtained from the participants for the publication of this case report.

CASE REPORTS

Case 1

A 55-year-old female presented to the clinic with multiple variably pigmented (light to dark brown), irregularly bordered solar lentigines on her left cheek and temporal area (Fig. 1A). The lesions had been present for over 20 years despite a prior laser treatment session. Intervention was performed using the 532-nm QS Nd:YAG VSLS system (Reepot; Classys Inc.) with an energy setting of 220 mJ and a fluence of 1.75 J/cm^2. Post-procedure, a hydrocolloid dressing (DuoDERM; ConvaTec) was applied and maintained for 2 weeks.

After 2 weeks of treatment, there was notable clearance of lentigines accompanied by mild erythema (Fig. 1B). By the 4 week, those lesions had fully resolved with no signs of PIH, persistent erythema, or scarring (Fig. 1C), and the therapeutic effects were maintained throughout the 3-months follow-up period (Fig. 1D).

Case 2

A 50-year-old female had two irregularly shaped, light brown solar lentigines on her right cheek and the nose (Fig. 2A), which remained refractory despite 8 years of

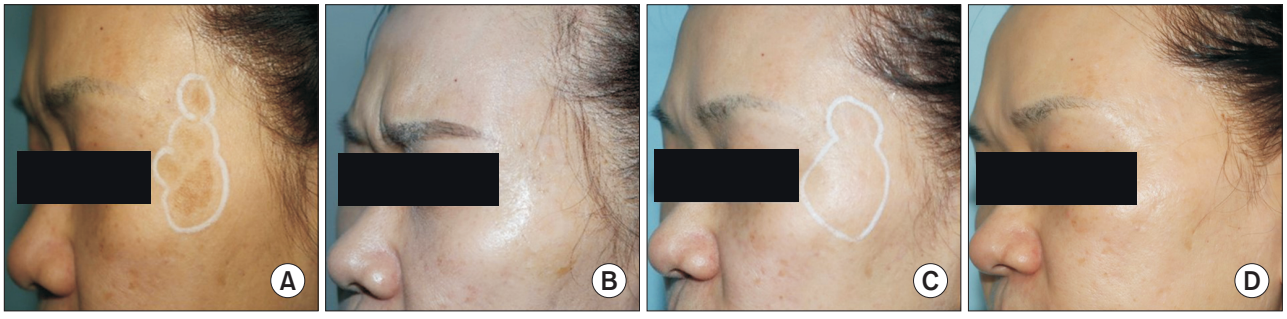

Fig. 1. Improvement of solar lentigines on the left cheek and temporal area following a single session of the 532-nm neodymium-doped yttrium aluminum garnet vasculature salvage laser surgery system: (A) before, (B) at 2 weeks, (C) 4 weeks, and (D) 3 months post-treatment.

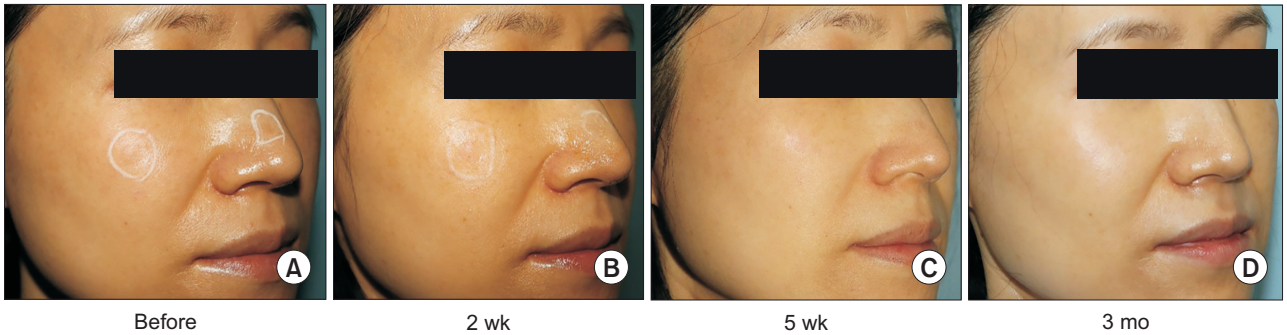

Fig. 2. Improvement of solar lentigines on the right cheek and nose area following a single session of the 532-nm neodymium-doped yttrium aluminum garnet vasculature salvage laser surgery system: (A) before, (B) at 2 weeks, (C) 5 weeks, and (D) 3 months post-treatment.

melasma treatment with laser toning and whitening. Treatment for resistant solar lentigines was performed using the VSLS system with the same parameters as Case 1, followed by 2 weeks of DuoDERM application.

At 2 weeks post-treatment, marked lentigines clearance and mild erythema were observed (Fig. 2B). By week 5, lentigines had completely resolved on the cheek and significantly faded on the nose, with no adverse effects (Fig. 2C). The therapeutic effects persisted for up to 3 months following treatment (Fig. 2D).

DISCUSSION

Lentigines are a common indication for cosmetic dermatologic procedures [1]. While various laser modalities, including the QS 532-nm Nd:YAG laser, are widely used, their application is often limited by adverse effects such as PIH, particularly in susceptible individuals [4-7]. Those cases demonstrate the efficacy of the novel 532-nm Nd:YAG VSLS system as a promising therapeutic option, especially for patients with suboptimal response to prior laser treatments.

A major limitation of conventional QS 532-nm Nd:YAG laser treatment for epidermal pigmented lesions is the risk of PIH [10]. Although the 532-nm wavelength is highly absorbed by melanin, it is also absorbed by hemoglobin in superficial dermal vessels, potentially causing thermal injury and initiating an inflammatory response [6]. This cascade may disrupt the basal cell layer and stimulate melanocyte activity, resulting in excess melanin deposition in the epidermis and dermis, clinically presenting as PIH [11]. This risk is particularly pronounced in individuals with darker skin phototypes (Fitzpatrick types III-VI), including Asian populations, often necessitating cautious parameter selection and contributing to patient hesitation [11].

The present study observed the complete clearance after a single session, with sustained therapeutic effects and no complications observed during the 3-months follow-up period, supporting the efficacy of the VSLS system in treating refractory solar lentigines. Consistent findings were reported by Lee et al. [8], where complete lesion clearance was achieved in six patients unresponsive to previous laser treatments, with only mild, transient erythema noted [4]. These results suggest a favorable safety profile and imply that the VSLS system may mitigate the risk of PIH, particularly in patients predisposed to this complication with conventional laser [11].

The favorable response observed in those cases, particularly in lentigines considered challenging to treat, may be attributed to the VSLS system's distinctive technological features. The CPTL contact cooling likely contributed by inducing vasoconstriction, thereby reducing hemoglobin interference and limiting non-specific thermal injury to surrounding upper dermal structures [9,12]. This vascular preservation is central to minimizing post-treatment inflammation and the subsequent risk of PIH [13]. By minimizing heat diffusion and inflammation, the system enables safer delivery of higher effective fluences to the melanin target [9]. Furthermore, the AutoDerm® technology ensures precise energy delivery confined to the lesion, enhancing efficacy while sparing adjacent normal skin [9]. This combination of targeted energy and optimized fluence may account for the effective clearance of solar lentigines within a relatively short duration.

This report has a limited number of patients and a short follow-up. Extended observation is required to evaluate the long-term efficacy and identify any delayed adverse effects or recurrence.

In conclusion, those cases illustrate that the 532-nm Nd:YAG VSLS system may offer a safe and effective treatment for facial lentigines, achieving rapid clearance, even in treatment-resistant cases, potentially within a single session. The system's integrated cooling and automated targeting features may help reduce common adverse effects such as PIH. Further validation through larger, controlled studies with standardized protocols and long-term follow-up is necessary to establish the clinical utility and safety of VSLS for lentigines and other pigmentary disorders.

ORCID

Ngoc Ha Nguyen, https://orcid.org/0009-0002-4466-9550
Jeanne Jung, https://orcid.org/0009-0003-3333-2503
Sang Ju Lee, https://orcid.org/0000-0003-2228-7121
Young In Lee, https://orcid.org/0000-0001-6831-7379

AUTHOR CONTRIBUTIONS

Conceptualization: NHN, JJ, SJL, YIL. Data curation: NHN, YIL. Formal analysis: NHN, YIL. Funding acquisition: NHN, YIL. Investigation: NHN, JJ, SJL. Methodology: NHN, JJ, SJL, YIL. Project administration: YIL. Software: NHN. Supervision: YIL. Validation: NHN, JJ. Visualization: NHN, JJ, SJL. Writing–original draft: NHN, JJ, SJL, YIL. Writing–review & editing: all authors.

CONFLICT OF INTEREST

No potential conflict of interest relevant to this article was reported.

FUNDING

This study was supported by a MEF Fellowship conducted as part of "Education and Research capacity building project at University of Medicine and Pharmacy at Ho Chi Minh City" implemented by the Korea International Cooperation Agency (KOICA) in 2025 (no. 2021-00020-4).

DATA AVAILABILITY

None.

ACKNOWLEDGMENTS

None.

SUPPLEMENTARY MATERIALS

None.

REFERENCES

1. Praetorius C, Sturm RA, Steingrimsson E. Sun-induced freckling: ephelides and solar lentigines. Pigment Cell Melanoma Res 2014;27:339-50.
2. Ho SG, Chan NP, Yeung CK, Shek SY, Kono T, Chan HH. A retrospective analysis of the management of freckles and lentigines using four different pigment lasers on Asian skin. J Cosmet Laser Ther 2012;14:74-80.
3. Mukovozov I, Roesler J, Kashetsky N, Gregory A. Treatment of lentigines: a systematic review. Dermatol Surg 2023;49:17-24.
4. Byun SJ, Kim WS, Choi YJ. Comparison of the picosecond and Q-switched Nd:YAG lasers in the treatment of pigmentary disorders: a retrospective case series in the Republic of Korea. Med Lasers 2024;13:25-34.
5. Vachiramon V, Iamsumang W, Triyangkulsri K. Q-switched double frequency Nd:YAG 532-nm nanosecond laser vs. double frequency Nd:YAG 532-nm picosecond laser for the treatment of solar lentigines in Asians. Lasers Med Sci 2018;33:1941-7.
6. Kang HJ, Na JI, Lee JH, Roh MR, Ko JY, Chang SE. Postinflammatory hyperpigmentation associated with treatment of solar lentigines using a Q-Switched 532-nm Nd: YAG laser: a multicenter survey. J Dermatolog Treat 2017;28:447-51.
7. Piccolo D, Fusco I, Crisman G, Zingoni T, Conforti C. Efficacy and safety of Q-Switched 1064/532 nm Nd:YAG lasers on benign hypermelanosis in dark-skinned individuals-a preliminary study. J Clin Med 2024;13:1615.
8. Lee SY, Kim KR, Kim S, Han HS, Hong JY, Seok J, et al. Refractory solar lentigines successfully treated with 532-nm nanosecond Nd:YAG vasculature salvage laser surgery (VSLS) system: case series. Skin Res Technol 2024;30:e70055.
9. Kim YH, Cheon YS, Jeong GH, Yook HJ, Han JH, Bang CH, et al. The efficacy and stability of 532 nm nanosecond Nd: YAG vasculature salvage laser surgery (VSLS) system in ex vivo pigmented micropig skin. Lasers Med Sci 2023;38:180.
10. Kim JY, Yang J, Huh G, Choi YJ, Kim WS. A split-face, single-blinded, randomized controlled comparison of 532 nm picosecond neodymium-doped yttrium aluminum garnet laser versus 532 nm Q-switched neodymium-doped yttrium aluminum garnet laser in the treatment of solar lentigines. Ann Dermatol 2020;32:8-13.
11. Silpa-Archa N, Kohli I, Chaowattanapanit S, Lim HW, Hamzavi I. Postinflammatory hyperpigmentation: a comprehensive overview: epidemiology, pathogenesis, clinical presentation, and noninvasive assessment technique. J Am Acad Dermatol 2017;77:591-605.
12. Manuskiatti W, Eimpunth S, Wanitphakdeedecha R. Effect of cold air cooling on the incidence of postinflammatory hyperpigmentation after Q-switched Nd:YAG laser treatment of acquired bilateral nevus of Ota like macules. Arch Dermatol 2007;143:1139-43.
13. Chaowattanapanit S, Silpa-Archa N, Kohli I, Lim HW, Hamzavi I. Postinflammatory hyperpigmentation: a comprehensive overview: treatment options and prevention. J Am Acad Dermatol 2017;77:607-21.

How to cite this article: Nguyen NH, Jung J, Lee SJ, Lee YI. Successful treatment of solar lentigines using a novel 532-nm nanosecond neodymium-doped yttrium aluminum garnet vasculature salvage laser surgery system: case series. Med Lasers 2025;14:181-184. https://doi.org/10.25289/ML.25.014