CLASSYS

REEPOT

Mechanism and Misconceptions of REEPOT for the Treatment of Solar Lentigines



Choi Seung(Cheongdam NOEL Clinic)



Although we live in a three-dimensional world, our visual system perceives only two-dimensional images. Our perception of three dimensions is, in a sense, a learned visual illusion. In physics, explanations of theories are usually accompanied by the condition that they apply within a specific "system." For example, when describing the laws of thermodynamics, the conditions may be explicitly restricted to a closed system. Considering too many variables in the pursuit of accuracy can make research difficult. Therefore, theoretical models often attempt to minimize the number of variables in order to reduce bias. However, difficulties often arise when these simplified theoretical conditions are applied to actual clinical practice.

Why 532 ㎚ is Suitable for Treating Solar Lentigines?

<Figure 1> is a very well-known illustration. It effectively visualizes the concept that the penetration depth of a laser beam due to scattering varies with the spot size. According to this theory, when treating tattoos – where most of the pigment is located in the dermis – with a 532 nm wavelength, treatment using a small spot size would be expected to be difficult. However, in actual clinical practice, this is not particularly challenging. A closer look at panel A and B of <Figure 1> reveals that the scales of the epidermis and dermis are depicted differently. In panel A, the spot size and the thicknesses of the two skin layers are exaggerated to facilitate understanding. In contrast, panel B represents the epidermis as a thin red line approximately 100 ㎛ thick and the dermis as a green line approximately 1 mm thick.

Considering that most benign facial pigmented lesions encountered in clinical practice are confined to the epidermis, I do not believe that differences in penetration depth according to spot size are particularly important. With this in mind, <Figure 2> reveals a limitation in <Figure 1A>. In <Figure 2>, the difference in scale between the epidermis and dermis is disregarded, and the two layers are depicted as having nearly the same thickness. The authors of this paper appear to have intended to emphasize that longer-wavelength lasers are more advantageous for the treatment of leg veins.

Although it is true that a 1064 nm long-pulsed laser is advantageous for treating leg veins, these images should not lead to the misconception that shorter-wavelength lasers cannot reach the dermis. In actual clinical practice, 532 nm and 595 nm long-pulsed lasers are widely used for the treatment of vascular lesions.

<Figure 3> shows that characteristic rete ridge elongation that is commonly associated with solar lentigines. Because the pigmentation appears to extend deeply toward the dermis and solar lentigines can be difficult to treat, it is easy to assume that the laser must penetrate deeply to achieve an effective treatment. This is one reason why some argue that a 532 nm wavelength is not suitable for treating solar lentigines.

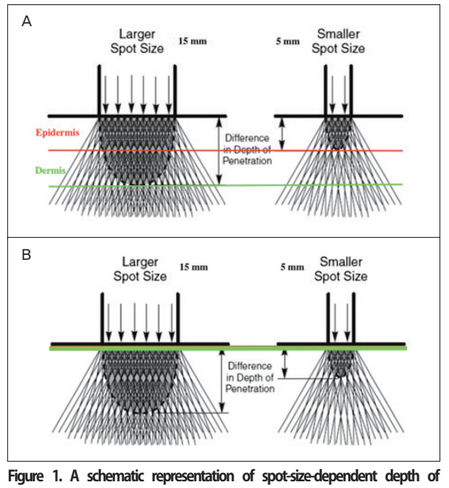

Figure 1. A schematic representation of spot-size-dependent depth of penetration. Source : Effect of wavelength and beam width on penetration in light-tissue interaction using computational methods, Ash, Caerwyn, et al., Lasers in medical science 32, (2017): 1909-1918, https://doi.org/10.1007/s10103-017-2317-4.

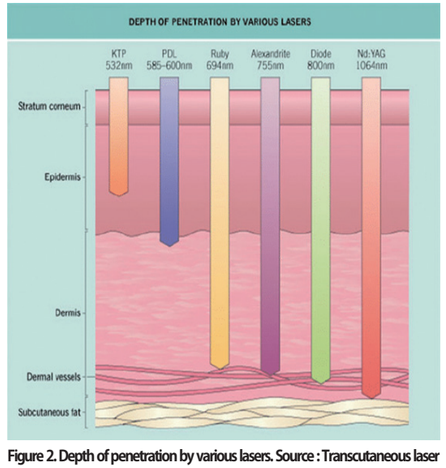

Figure 2. Depth of penetration by various lasers. Source : Transcutaneous laser treatment of leg veins, Arne A Meesters et al., Lasers in Medical Science 29(2), November 2013, DOI:10.1007/s10103-013-1483-2.

However, facial solar lentigines are much more commonly characterized by a relatively flat epidermis than by the elongated rate ridges shown in <Figure 3>. In addtion, in chronically and severely photoaged skin, both the epidermis and dermis are often atrophic.

Various Effects of VSLS

Taken together, the characteristics of REEPOT, which involves overlapping beams from a 532 nm Q-switched laser, cannot be considered a disadvantage in the treatment of solar lentigines. If REEPOT had not been equipped with the sufficiently powerful and sustained supercooling system it has today, it would likely not have survived in the market.

The key advantage of REEPOT lies not in the 532 nm wavelength itself, but in its supercooling system. The combination of supercooling and laser irradiation represents a fundamentally different concept from that of conventional laser treatments.

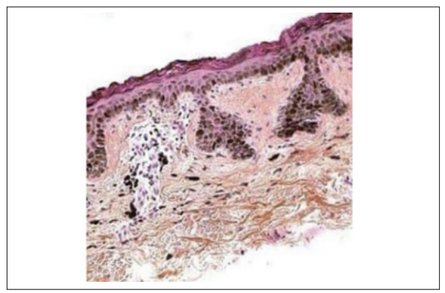

Figure 3. Solar lentigo with elongation of rete ridges and intensely pigmented keratinocytes. Courtesy: Mungfall.com, Daub, Discolouration, Pigmentation-Solar Lentigo, Bajaj, Anubha, Annals of Dermatological Research 3.1(2019): 001-006, https://www.dermatojournal.com/apdf/adr-aid1006.pdf.

One of the proposed mechanisms of REEPOT, VSLS (Vascular Savage Laser Surgery), involves instantaneous supercooling that constricts blood vessels, thereby minimizing hemoglobin—the relative chromophore—within the laser irradiation field and substantially reducing vascular damage. After treatment, the recovered capillaries may then contribute to scar repair during the healing process of normal tissue.

Another consideration regarding the supercooled state is that, as the temperature approaches approximately 4° C, the density of water increases, and proteins mixed with water—the most abundant component inside and outside cells—may transition into a cytogel-like state. This could temporarily and markedly reduce intracellular signal transduction. This may help explain why REEPOT treatment can be performed without anesthesia despite the overlapping delivery of relatively high laser energy.

In addition, while melanin-laden keratinocytes are completely destroyed, thermal diffusion to the surrounding normal keratinocytes is reduced by supercooling, thereby minimizing collateral tissue damage.

One important consequence of reduced intracellular signaling may be the suppression of inflammation. In capillaries protected by supercooling, the activity of inflammatory cytokines may be markedly reduced, potentially lowering the risk of complications such as post-inflammatory hyperpigmentation (PIH).

Following REEPOT treatment, a wound dressing is applied to the treated area for two weeks. During this period, there is usually very little exudate, so the dressing does not need to be changed frequently. This may also be related to the effects of supercooling.

The Peltier-based cooling system incorporated into REEPOT has demonstrated the best performance among all the devices I have experienced to date. Recently, many devices, including monopolar RF systems, have incorporated cooling technologies; however, I have often found their cooling intensity and duration to be insufficient. If the cooling technology used in REEPOT were incorporated into future CLASSYS devices, I believe it could contribute to improved treatment outcomes. In energy-based devices (EBDs), cooling not only protects the epidermis but may also provide therapeutic effects in its own right. Cooling appears to affect not only the epidermis but also the dermis, although with a certain time lag. The global aesthetic medicine market is growing rapidly. In particular, the EBD market, led by monopolar RF devices, has become increasingly competitive. In this environment, I believe that devices capable of delivering the most effective and sustained cooling may ultimately have the greatest longevity in the market.

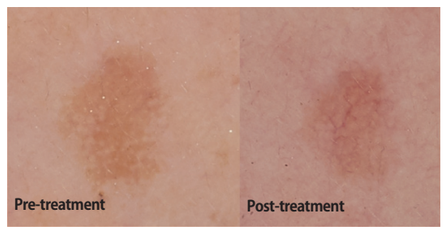

Figure 4. Branching telangiectasia observed after the treatment of solar lentigines. Courtesy of Dr. Seung Choi.

Telangiectasia Dermal Melanophage

<Figure 4> shows the appearance after five treatments of solar lentigines using a 755 nm long-pulsed laser at 2-week intervals. Although the epidermal lentigines were effectively removed, telangiectasia is visible at the level of the superficial vascular plexus in the upper dermis. These are pre-existing vessels beneath the lentigines that become visible after treatment; however, from a distance, they can make it appear as though the lentigines have not been completely removed. A considerable proportion of patient complaints following pigment treatment are related to this type of appearance. For this reason, clinical photography is extremely important in pigment treatment. Properly documented photographs can help prevent misunderstandings and reduce patient complaints. When the vessels are clearly visible, as in <Figure 4>, they can be treated with a vascular laser. If not, they generally resolve spontaneously within 1 - 2 months.

Dermal melanophages are among the most challenging findings to manage. <Figure 5> shows



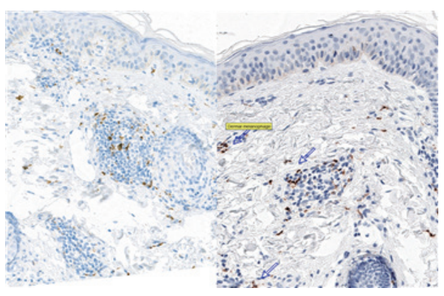

Figure 5. Pre and Post treatment of solar lentigines in a 39 year old female patient(top), and histopathologic image after treatment(bottom). Courtesy of Dr. Seung Choi.

image from a patient with solar lentigines in whom pigmentation persisted even after 10 treatment sessions.

Although such cases are uncommon, most solar lentigines that are difficult to treat or remain faintly visible after treatment were associated with dermal melanophages. Based on these observations, it can be said that rete ridge elongation does not necessarilymake treatment difficult. Although many may question this view, solar lentigines on the arms and legs can usually be treated successfully with a single REEPOT session. The wound dressing is kept in place for approximately three weeks, and even if residual erythema remains, no additional treatment is usually required after 2 - 3 months. Clinicians who have actually performed the procedure are likely to agree with this observation.

There is no easy or rapid way to eliminate dermal melanophages. In most cases, they gradually resolve with treatment over approximately 3 - 6 months, although treatment may occasionally need to continue for more than a year. When solar lentigines are located over melasma or near the mandibular line, treatment is generally not particularly difficult if performed with appropriate caution. In such cases, however, it is important to obtain good clinical photographs before treatment, carefully assess the presence of telangiectasia and dermal melanophages, and provide the patient with a thorough explanation before the procedure.

Laser treatment for pigmented lesions can be very challenging. However, mastering it can serve as a valuable shield in today’ s highly competitive environment. I describe it as a shield rather than a spear because it can help clinicians navigate difficult times more reliably. Even without additional spending on advertising or promotion, there is steady demand for pigment treatment, and few approaches are more effective in building patient trust. When a clearly visible solar lentigo is completely removed, the patient is likely to develop strong confidence in the physician, while the physician, in turn, gains greater confidence in the treatment approach.