

Vulvar Rejuvenation Using High-Intensity Focused Ultrasound (HIFU): Fundamentals and Technique

Fábio dos Santos Borges^{1*}, Mylana Almeida de Carvalho², Carla Barreto Silva de Cerqueira², Tais Andrade Cravo Monteiro², Isabelle Maria Almeida e Benevides³, Adriele Machado Dantas³, Thiago Gusmão da Silva⁴, Carolina Barreto Ribeiro Martins dos Santos⁵

¹Estácio de Sá University, Rio de Janeiro, Brazil

²IDE Faculty—Institute for Educational Development, Salvador, Brazil

³Longevitat Clinic—Advanced Aesthetics, Salvador, Brazil

⁴FAINOR, Independent College of the Northeast, Vitória da Conquista, Brazil

⁵UFBA, Federal University of Bahia, Salvador, Brazil

Email: *fabioborges2000@gmail.com

How to cite this paper: Borges, F.S., de Carvalho, M.A., de Cerqueira, C.B.S., Monteiro, T.A.C., Almeida e Benevides, I.M., Dantas, A.M., da Silva, T.G. and dos Santos, C.B.R.M. (2022) Vulvar Rejuvenation Using High-Intensity Focused Ultrasound (HIFU): Fundamentals and Technique. *Journal of Biosciences and Medicines*, 10, 239-252.

<https://doi.org/10.4236/jbm.2022.1012019>

Received: November 26, 2022

Accepted: December 26, 2022

Published: December 29, 2022

Copyright © 2022 by author(s) and Scientific Research Publishing Inc.

This work is licensed under the Creative

Commons Attribution International

License (CC BY 4.0).

<http://creativecommons.org/licenses/by/4.0/>



Open Access

Abstract

Background: The unaesthetic appearance of the female intimate area (vulva, “mound of venus” and perianal region) is a triggering factor of negative psychological responses, embarrassment, anxiety and insecurity in many women. Using rejuvenating equipment for vaginal structure or for the intimate area as a whole is already widespread in the literature, and High-Intensity Focused Ultrasound (HIFU) has proven to be very effective in the clinical practice of many professionals. This study, therefore, aims to describe the fundamentals and applicability that guide the use of HIFU in vulvar rejuvenation. **Materials and Methods:** Exploratory research was carried out, presented in a narrative review, to highlight the action of HIFU in female intimate rejuvenation. The review explored scientific articles published and available in the following databases: MEDLINE (Medical Literature Analysis and Retrieval System Online), PubMed (National Library of Medicine), SCIELO (Scientific Electronic Library Online), and LILACS (Latin Literature American and the Caribbean in Health Sciences). In addition, some clinical findings obtained through a retrospective analysis of medical records were added to describe the authors’ clinical experience in the use of Focused Ultrasound (HIFU) for vulvar rejuvenation. **Results:** We verified that the tissues of female external genitalia respond very well to the stimuli of the focused sound waves of the HIFU, being able to produce immediate and lasting results through isolated applications or in association with intradermotherapy or other therapeutic resources. **Conclusion:** We conclude that using High Intensity Focused Ultrasound aimed at

vulvar rejuvenation is safely indicated and assures excellent aesthetic results at the end of the treatment because similarly to other treatment techniques, the thermal stimuli of HIFU are also able to produce an excellent therapeutic response in the dermal tissue of the female intimate area, promoting intense neocollagenesis and generating great aesthetic improvement.

Keywords

Intimate Aesthetics, Vulvar Rejuvenation, Vaginal Rejuvenation, HIFU, Focused Ultrasound, Micro Focused Ultrasound, and Cosmetic Gynecology

1. Introduction

Currently, there has been an increase in demand for aesthetic procedures able to treat the female intimate region. However, for some women, the desire for these therapies is still complex since it can affect various physical and psychological aspects of the woman's life. Therefore, aesthetic alterations resulting from the natural aging process or aggravated by external factors related to daily life habits (smoking, excess alcohol, use of medication), as well as those from vaginal delivery childbirth, surgical sequelae, physiological changes resulting from a lifetime sexually active, sports (such as cycling) and others, are part of the daily lives of professionals who work in the treatment of aesthetic dysfunctions of the female intimate region.

It is important to mention there is no pre-established beauty standard for the female external genitalia, but what pleases or bothers the woman. Thus, it is understood that the unpleasant aesthetic appearance of the female intimate region (vulva, "mound of venus", perianal region, etc.) is a relevant point in cases of increased negative psychological responses, embarrassment, anxiety and insecurity [1]; therefore, this can guide the search for treatment of the intimate area and the choice of the most effective therapeutic resource for each case (essential for rescuing female self-esteem), since that sometimes the visual aspect and functionality of the introitus are marked in the majority sometimes as responsible for sexual disorders and reduced quality of life [2].

The use of rejuvenating equipment including the intimate area is already widespread in the literature, for instance, mainly radiofrequency (RF), which through an increase in temperature promotes stimuli at the cellular level capable of promoting an improvement in the quality of the vulvar tissue [3] [4]. High Intensity Focused Ultrasound (HIFU) was initially described as a non-invasive treatment for facial sagging, as it has the ability to reach deeper tissues without damaging the epidermis, by the production of small controlled thermal coagulation points in the reticular dermis medium and/or deep, being able to reach even the superficial muscular aponeurotic system (SMAS), might generate an immediate contraction/retraction of the thermally denatured collagen, initiating a neocollagenesis and the remodeling of the collagen with subsequent cutaneous

tissue stiffening in a non-invasive way [5].

HIFU can induce neocollagenesis in the middle and lower reticular dermis, and neoelastogenesis in the deep reticular dermis. In a comparative study between monopolar radiofrequency and HIFU [6], the authors have concluded that RF affects tissue more diffusely while HIFU causes more focal collagen induction.

Currently, the use of HIFU in the intimate area has already been described by several authors [7] [8] [9] with the aim of treating vaginal atrophy and laxity, urinary incontinence, non-surgical vaginoplasty and other conditions; however, no consistent reports were found associating the use of high-intensity focused ultrasound for the aesthetic rejuvenation of the external genitalia.

Afterall, this study aimed to describe the fundamentals that guide the High-Intensity Focused Ultrasound utilization in vulvar rejuvenation presenting data about fundamentals that direct its use in an effective and safe way as well as the findings obtained by the clinical practice of the authors.

2. Materials and Methods

This study is characterized by exploratory research written as a narrative review to highlight the action of high-intensity focused ultrasound (HIFU) in vulvar rejuvenation. The review explored scientific articles, published and available in the following databases: MEDLINE (Medical Literature Analysis and Retrieval System Online), PubMed (National Library of Medicine), SCIELO (Scientific Electronic Library Online) and LILACS (Latin American and Caribbean Literature in Health Sciences).

As inclusion criteria, it was selected sources that mentioned aesthetic condition of the female intimate area or described the fundamentals of using HIFU related to skin rejuvenation and toning. Sources that did not present the abstract, were not allocated in scientific journals and did not address the subject of the study. Also, the same for those that did not support the collection of reliable data, were discarded.

The bibliographic survey was carried out in Portuguese and English, with the following descriptors: Intimate aesthetics, vulvar rejuvenation, vaginal rejuvenation, HIFU, focused ultrasound, micro focused ultrasound, and cosmetic gynecology.

In addition to the bibliographic review, some treatment protocols for vulvar rejuvenation were added to this work based on authors clinical practice using high-intensity focused ultrasound, associated or not with other therapeutic resources.

3. Results and Discussion

High Intensity Focused Ultrasound (HIFU) was developed for a non-surgical treatment, aiming at skin retraction by stimulating the creation of new collagen and elastin [10].

HIFU is a device designed to produce small microthermal zones of coagulation in the middle reticular layer, the deepest of dermis and subdermis (SMAS), leading to a wound healing response leading to tissue contraction and new collagen production or reduction of adiposities and cellulite [11] [12].

Local absorption of energy causes intermolecular vibration and produces heat (over 65°C), enough for collagen denaturation at thermal coagulation points (TCP) (approximately 1 mm³ to 1.5 mm³) [13].

From the thermal injury the tissue repair process begins. According to some authors [14], the evolutionary healing process from 48 hours post-injury occurs as follows: 1) From the first 48 hours to 10 weeks after treatment: Inflammation stimulates fibroblast proliferation, neocollagenesis and elastogenesis around TCPs; 2) On the 28th day: adjacent dermis undergoes remodeling and viscoelasticity increases; 3) Over time, the skin becomes thicker and tenser, further increasing the elastin in the injured area and the collagen in the reticular dermis; 4) 10 weeks after treatment: Collagen is completely replaced in the treated areas, there is greater tightening and lifting of the skin—this remodeling may last up to a year.

Authors [15] found that 45 days after treatment there was already an evident increase in the number and size of fibroblasts in the treated group, as well as a greater number of blood vessels and inflammatory cells compared to the control group. Also, they found that there was already an evident rising in collagen type I compared to collagen type III (Figure 1).

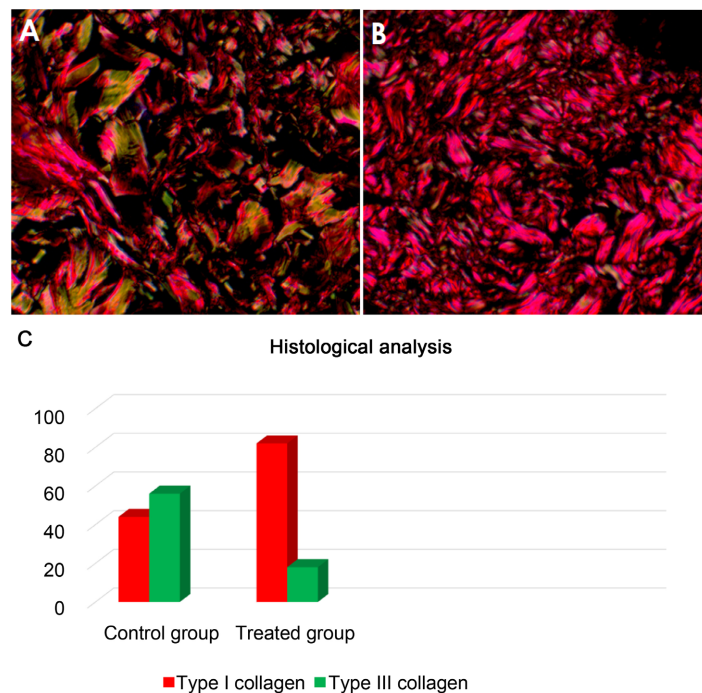


Figure 1. Histological analysis (A) Control Group with type III collagen predominance (green—56%); (B) Group treated with expressed increase of type I collagen (orange color—82%), when compared to type III collagen (green—18%); (C) Comparative graphic (Source: Meyer *et al.* (2021) [15]—Reproduced with authorization.).

Although the literature commonly describes a late effect on skin components and an improvement in the aesthetic appearance after the use of HIFU, in our clinical practice we identify immediate effects on the skin, both in facial treatments (**Figure 2**) and in treatments of the intimate area (**Figure 3**). The reason for these findings is the thermal action of HIFU on the fibrous tissue constituting the SMAS (“lifting effect”), as well as on the collagen of the reticular dermis [10] [16] [17].

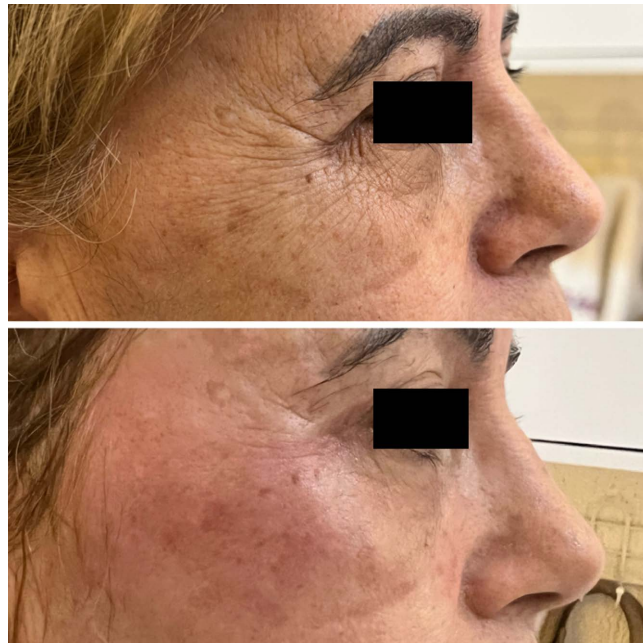

Figure 2. Immediate effect of High Intensity Focused Ultrasound in the periorbicular region of the eyes (7 Mhz - 3.0 mm and 10 Mhz - 1.5 mm transducers were used - Ultramed® manufactured by Medical San Ind Equipment’s Med, Brazil.).

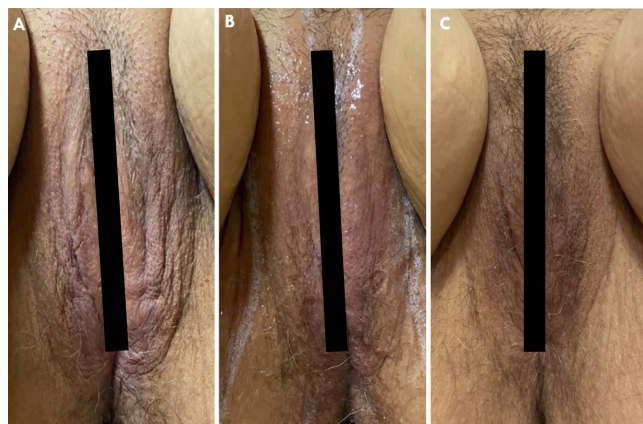

Figure 3. (A) Vulvar region before treatment; (B) Immediate effect of high intensity focused ultrasound; (C) Late aesthetic effect, 40 days after 1 treatment session (7 Mhz - 3.0 mm and 1.5 mm transducers were used—Ultraformer III® manufactured by CLASSYS INC., Seoul, Korea.).

Despite the remarkable immediate effect on the skin, HIFU has proven to be even more efficient in the long term. Authors [18] reported that the interval for a reevaluation, in order to judge the results, may vary from 2 to 6 months; however, Suh *et al.* (2016) [19] treated individuals with a total of 3 sessions of Focused Ultrasound with intervals of 4 weeks between sessions.

Based on these reports, in our clinical practice we have been suggested that clients return for reassessment 30 or 40 days after the procedure (especially when the immediate effects on the skin in the intimate area are not so evident) in order to reassess them for evaluating whether the initially proposed treatment plan should be maintained or changed according to the results obtained after this period. Corroborating and justifying the clinical practice of the authors of the present study, Ko *et al.* (2017) [20] reassessed skin elasticity in individuals treated with HIFU 4 and 12 weeks after 1 treatment session. Authors also reported that there was a significant improvement in the first reassessment (4 weeks) after HIFU treatment, and when reassessing the same individuals again 12 weeks after treatment they did not identify significant changes in elasticity improvement compared with what was verified in the first reevaluation.

In our cases of vulvar rejuvenation care where no apparent result was obtained, 30 or 40 days after the consultation, it was evaluated the possibility of associating other therapeutic resources such as electrotherapy and/or intradermotherapy was to assure and/or enhance the results. In **Figure 3** and **Figure 4**, it is possible to visualize the satisfactory evolution after 40 days of the initial treatment for vaginal rejuvenation.

In line with our clinical practice, we recommend the use of 3.0 and 1.5 mm transducers for vaginal rejuvenation combined in each treatment session. Nonetheless, other forms of application have been seen in the intimate rejuvenation market, and these use depths of 2.0 mm and even 4.5 mm.

In line with our clinical practice, we recommend the use of 3.0 and 1.5 mm transducers for vaginal rejuvenation, combined in each treatment session. However, other forms of application have been seen in the intimate rejuvenation

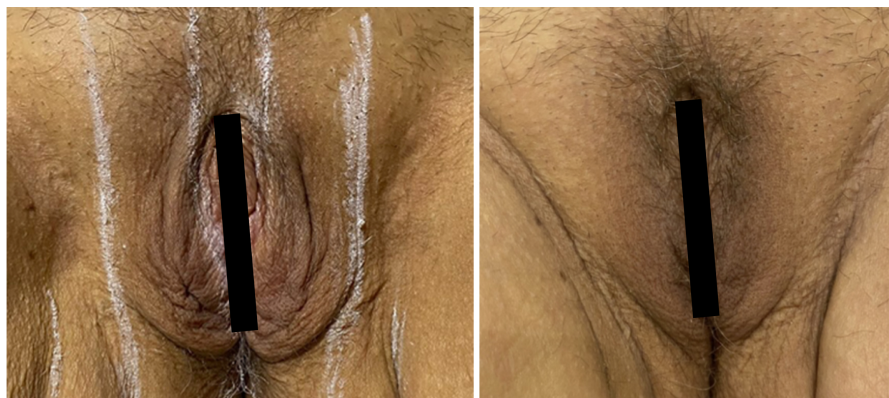

Figure 4. Late aesthetic effect, 40 days after 1 treatment session with High Intensity Focused Ultrasound (7 Mhz - 3.0 mm and 1.5 mm transducers were used—Ultraformer III® manufactured by CLASSYS INC., Seoul, Korea.).

market, and these use depths of 2.0 mm and even 4.5 mm.

Based on the study by Oni *et al.* (2014) [21], the number of TCP lines suggested for the treatment of the external part of the intimate area is, on average, 20 to 30 lines on each side (Figure 5), for each depth. Usually, 40 to 60 lines are achieved in total when using only two transducers without the Vertical Vectoring technique.

Some authors recommended the overlapping of lines of TCPs, the Vertical Vectoring technique [22] [23] (also popularly called the “Hashtag” technique). That technique consists of performing lines of TCPs in the horizontal and vertical directions, overlapping them in the same treated region and increasing the number of points deposited. An advantage of this approach is the possibility of using lower energies and generating more comfort for the client without prejudice to the contraction of skin collagen, due to the greater number of TCPs per region.

Currently, we have consistently applied Vertical Vectoring for vulvar rejuvenation, using 3.0 mm and 1.5 mm transducers with safety and good results (Figure 6 and Figure 7).

The distance between the lines of TCPs ranges from 2 to 5 mm [18]. This might be adjusted to make with it occurs automatically during the delivery of TCPs

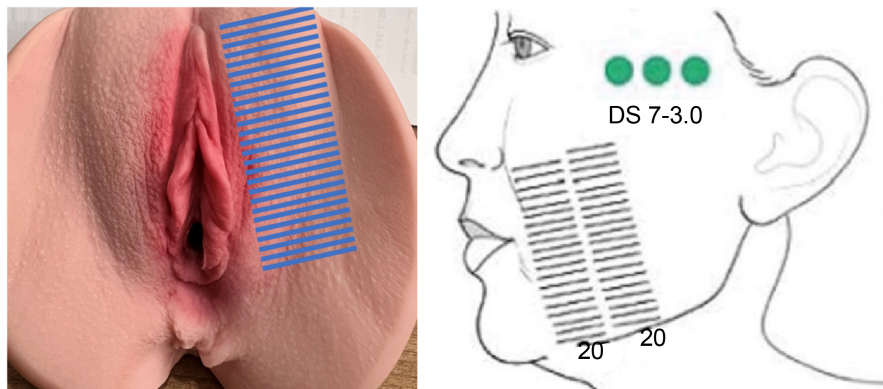


Figure 5. Scheme illustrating line distribution of HIFU TCPs for vaginal rejuvenation (Adapted from Oni *et al.*, 2014 [21].).

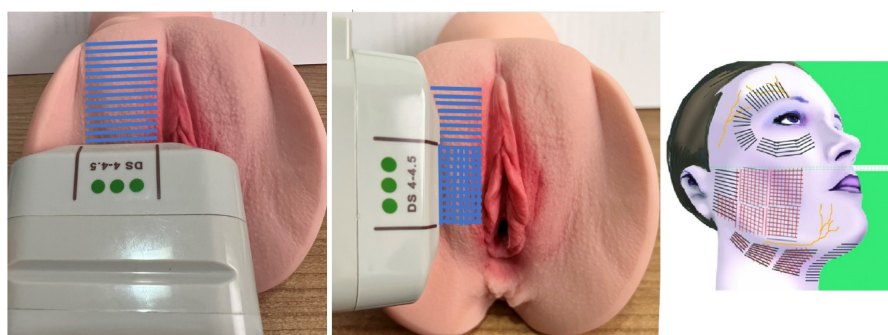

Figure 6. Scheme illustrating the distribution of lines of HIFU TCPs with the Vertical Vectoring (“Hashtag”) technique for vulvar rejuvenation. (Adapted from Werschler & Werschler, 2016 [22].).

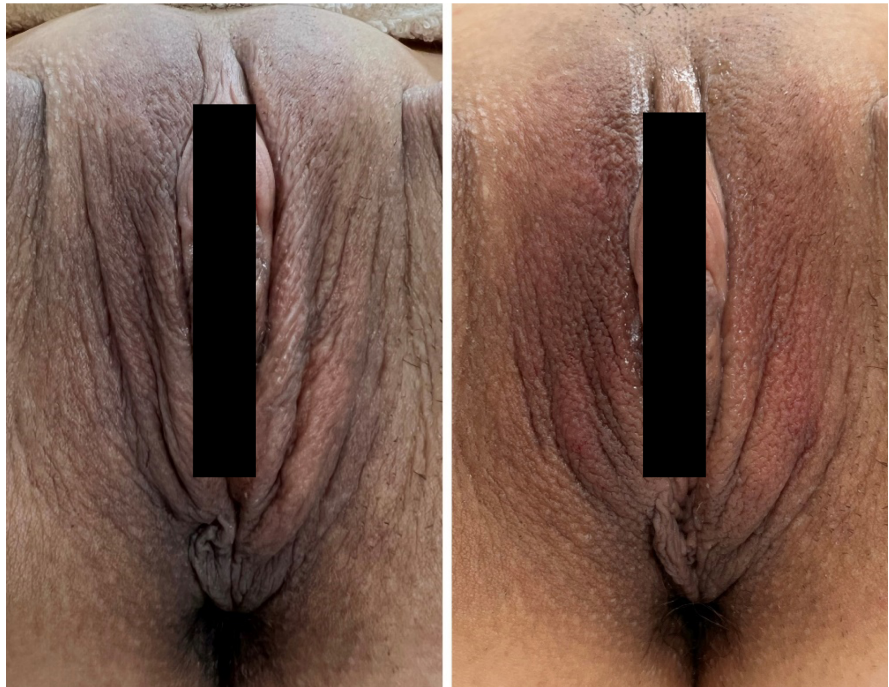


Figure 7. Immediate effect of using the Vertical Vectoring (“Hashtag”) technique in vulvar rejuvenation, using 7 Mhz - 3.0 mm and 1.5 mm transducers (Total of 68 TCP lines with each transducer.) (Ultraformer III® manufactured by CLASSYS INC., Seoul, Korea.).

using “multiline” transducers, but with the use of “single-line” transducers. This procedure is characterized as operator-dependent and it will require the professional’s dexterity so that there is no damage to the results due to the non-uniformity in the delivery of TCP lines. In our clinical practice, we try to distance the lines by about 3 millimeters between them.

According to Lee *et al.* (2012) [24], the spacing between thermal coagulation points must be related to depth. Thus, a distance of 1.5 mm between the points must be adjusted in the equipment when energy is supplied at a depth of 4.5 mm; 1.1 mm distance between points when power is supplied at a depth of 3.0 mm. For Jeon *et al.* (2018) [25], cartridges with depths of 1.5 mm and 3.0 mm should be used with a distance between points of 1.2 mm.

In the treatment of aesthetic dysfunctions, both on the face and on the external genitalia, considering that we primarily use depths of 3.0 mm and 1.5 mm we recommend 1.2 mm as the ideal distance between TCPs. If the client complains that these parameters are very uncomfortable, it is possible to reduce or increase the distance between the clotting points to 1.3 to 1.5 mm.

With regard to the energy dose (Joules) used, there is difficulty in standardizing it due to the fact only one model of equipment was used in our clinical practice and teaching, and thus, we recommend that the dose be compatible, initially, as the customer’s tolerance level. Therefore, the professional can use dose control measures such as directly decreasing the energy and/or increasing the distance between the TCPs. There are clients who cannot tolerate pain and may need medication to alleviate their discomfort.

Working in the intimate area with HIFU revealed a problem for some professionals regarding antisepsis measures and/or degerming the transducer after use (autoclaving is not recommended for transducers since their structure contains many electronic components that could be damaged once exposed to high temperatures). In view of this, with the aim of reducing the risk of disease transmission among clients through the “shared use” of the transducer, an efficient measure to be adopted is to use a sheet of plastic film over the wave sound emission area of the transducer (to avoid contact of the device with the external genital structure (**Figure 8**)). It is important to highlight that it is extremely important to use a good layer of common gel between the transducer and the plastic film when preparing it for application. And, after its use, it must be discarded.

Finally, we emphasize the importance of High Intensity Focused Ultrasound (HIFU) associations with other resources mainly with intradermotherapy techniques. In traditional applications, especially on the face, collagen biostimulators already find support in the literature [26] [27] and products based on calcium hydroxyapatite are becoming very known in clinical practice of many professionals [11] [28] [29] [30], as well as hyaluronic acid [31] and polylactic acid [32].

For vulvar rejuvenation, in our clinical practice we have also been using collagen biostimulators from the Brazilian industry (sterile base products for multipurpose use in the aesthetics segment) that are composed of several active ingredients which ones have a potentiating action to increase dermal collagen. **Figure 9** and **Figure 10** show some effects of associating of HIFU with some biostimulators.

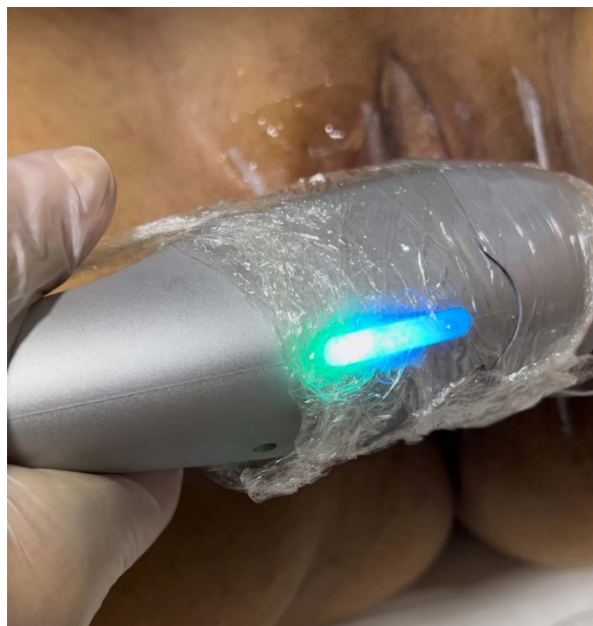

Figure 8. Protection of the HIFU transducer with plastic film for use in the intimate area.

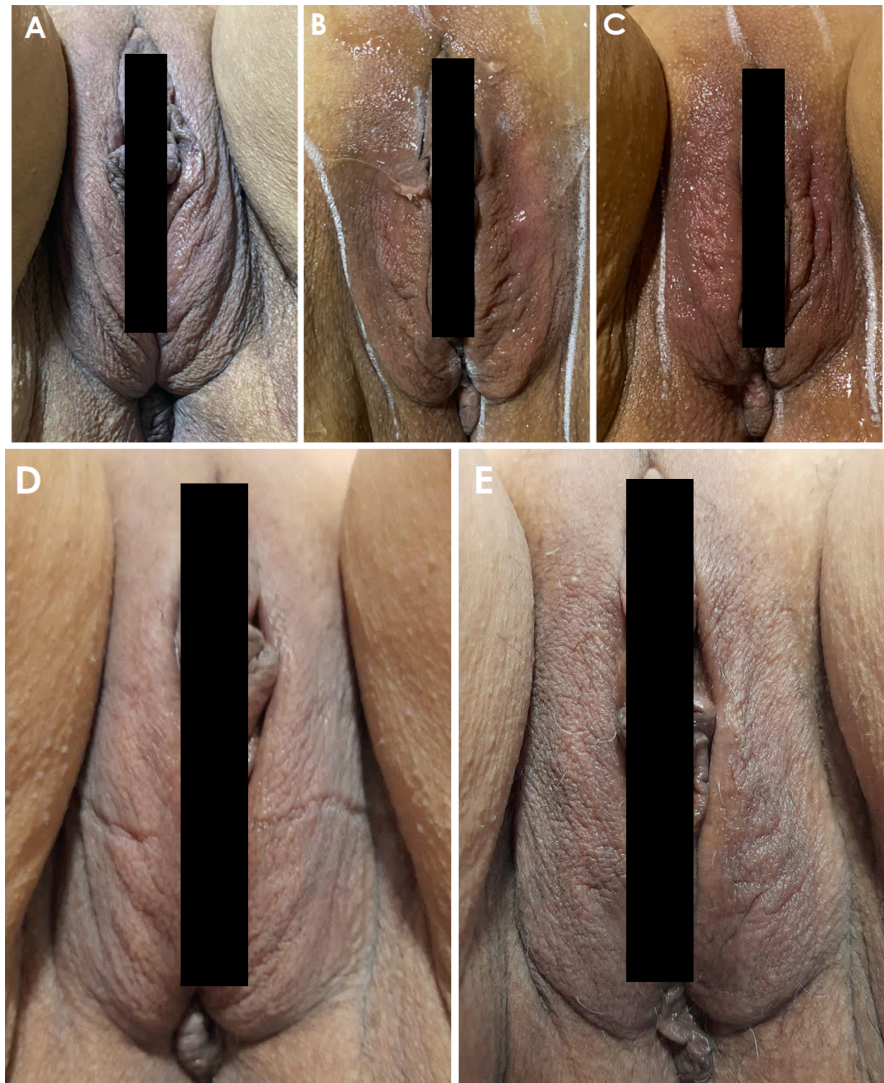


Figure 9. Association of Microfocused Ultrasound with collagen biostimulator: (A) Before treatment; (B) Immediate effect of HIFU (Ultraformer III® manufactured by CLASSYS INC., Seoul, Korea.); (C) Right after the injection of Sculpt Derm Collagen Booster® (Cosmobeauty Ind Com Cosmetics, Brazil.); (D) 45 days after the 1st treatment session; (E) 90 days after treatment.

4. Conclusions

This study shows that the conventional applicability of High Intensity Focused Ultrasound, both on the face and body, might be replicated in vulvar rejuvenation treatments with guaranteed safety and efficacy.

Furthermore, it is notorious that, just as radiofrequency, fractional laser or plasma jet produce an excellent therapeutic response in the skin in the female intimate area, the thermal stimuli produced by the use of HIFU are also able to promote intense neocollagenesis in the dermal tissue, *i.e.*, guarantees an excellent vulvar rejuvenation response and improves the aesthetic appearance of the region. Additionally, we identified that the association of collagen bio stimulating products is fully indicated when the aim is to enhance the production of

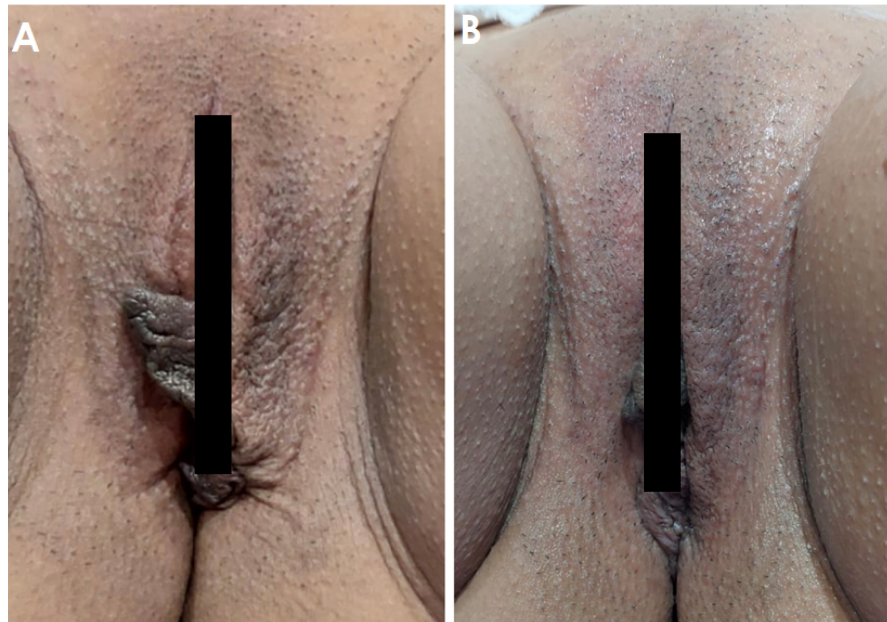

Figure 10. Association of focused ultrasound with collagen biostimulator: (A) Before treatment; (B) Immediate effect of HIFU (Ultramed® manufactured by Medical San Ind Equipment's Med, Brazil.) associated with the injection of Flacidez® (Mezzo Ind Cosmetics, Brazil.).

dermal collagen in the intimate area.

Finally, we conclude that the use of High Intensity Focused Ultrasound is a promising, safe and extremely effective adjuvant alternative to support the treatment of unsightly conditions in the female intimate region.

Conflicts of Interest

The authors declare no conflicts of interest regarding the publication of this paper.

References

- [1] Moore, R.D., Miklos, J. and Chinthakanan, O. (2014) Vaginal Reconstruction/Rejuvenation: Is There Data to Support Improved Sexual Function? An Update and Review of the Literature. *Surgical Technology International*, **25**, 179-190.
- [2] Pauls, R.N., Fellner, A.N. and Davila, G.W. (2012) Vaginal Laxity: A Poorly Understood Quality of Life Problem; a Survey of Physician Members of the International Urogynecological Association (IUGA). *International Urogynecology Journal*, **23**, 1435-1448. <https://doi.org/10.1007/s00192-012-1757-4>
- [3] Fistončić, I., *et al.* (2016) Short Time Efficacy and Safety of Focused Monopolar Radiofrequency Device for Labial Laxity Improvement-Noninvasive Labia Tissue Tightening. A Prospective Cohort Study. *Lasers in Surgery and Medicine*, **48**, 254-259. <https://doi.org/10.1002/lsm.22450>
- [4] Lordélo, P., Leal, M.R., Brasil, C.A., Santos, J.M., Lima, M.C. and Sartori, M.G. (2016) Radiofrequency in Female External Genital Cosmetics and Sexual Function: A Randomized Clinical Trial. *International Urogynecology Journal*, **27**, 1681-1687. <https://doi.org/10.1007/s00192-016-3020-x>

- [5] Neri, J.C.V., Souza, D.A.S., Dantas, J.B.L., Lima, A.A.M. and Silva, A.M. (2023) Aplicação do ultrassom microfocado no rejuvenescimento facial: Uma revisão da literatura. *International Journal of Science Dentistry*, **1**, 137-146.
- [6] Mishra, P.C., Mihai, D., Khurana, N. and Jabbar, M. (2021) Cosmetic Gynecology: Present and Future Perspectives. *International Journal of Innovative Research in Medical Science*, **6**, 845-853. <https://doi.org/10.23958/ijirms/vol06-i11/1273>
- [7] Elías, J.A., Galich, M., Corin, G., Garcia, P.N., Sivo, V., Nestor, D. and Nuñez, L. (2019) Management of Vaginal Atrophy, Vaginal Hyperlaxity and Stress Urinary Incontinence with Intravaginal High-Intensity Focused Ultrasound (HIFU). *International Journal of Obstetrics and Gynaecology Research*, **6**, 735-765.
- [8] Elrashidy, R.A. (2022) High Intensity Focal Ultrasound (HIFU) for Management of Vaginal Laxity with Impact on Sexual Satisfaction. *International Journal of Scientific Development and Research*, **7**, 308-311.
- [9] Altaf, F., Tabassum, R. and Atiq, S.R. (2022) Narrative Review Article “Aesthetic Gynecology”. *Journal of MAR Gynecology*, **3**, 1-17.
- [10] Lowe, S. (2021) Single Treatment, Single Depth Superficial Microfocused Ultrasound with Visualization for Rhytid Improvement. *Plastic and Reconstructive Surgery—Global Open*, **9**, e3662. <https://doi.org/10.1097/GOX.0000000000003662>
- [11] Casabona, G. and Pereira, G. (2017) Microfocused Ultrasound with Visualization and Calcium Hydroxylapatite for Improving Skin Laxity and Cellulite Appearance. *Plastic and Reconstructive Surgery—Global Open*, **5**, e1388. <https://doi.org/10.1097/GOX.0000000000001388>
- [12] Friedman, O., Isman, G., Koren, A., Shoshany, H., Sprecher, E. and Artzi, O. (2020) Intense Focused Ultrasound for Neck and Lower Face Skin Tightening a Prospective Study. *Journal of Cosmetic Dermatology*, **19**, 850-854. <https://doi.org/10.1111/jocd.13313>
- [13] Brobst, R.W., Ferguson, M. and Perkins, S.W. (2012) Ulthera: Initial and Six Month Results. *Facial Plastic Surgery Clinics of North America*, **20**, 163-176. <https://doi.org/10.1016/j.fsc.2012.02.003>
- [14] Park, J.Y., Lin, F., Suwanchinda, A., Wanitphakdeedecha, R., Yu, J., Lim, T.S., Chen, J.F., et al. (2021) Customized Treatment Using Microfocused Ultrasound with Visualization for Optimized Patient Outcomes: A Review of Skin-Tightening Energy Technologies and a Pan-Asian Adaptation of the Expert Panel’s Gold Standard Consensus. *The Journal of Clinical and Aesthetic Dermatology*, **14**, E70-E79.
- [15] Meyer, P., Meleck, M., dos Santos Borges, F., Fortuny, E., Farias, S., Afonso, F., Soares, C., de Morais Carreiro, E., da Silva, R. and Barbosa, A. (2021) Effect of Microfocused Ultrasound on Facial Rejuvenation: Clinical and Histological Evaluation. *Journal of Biosciences and Medicines*, **9**, 112-125. <https://doi.org/10.4236/jbm.2021.97012>
- [16] White, W.M., Makin, I.R., Barthe, P.G., Slayton, M.H. and Gliklich, R.E. (2007) Selective Creation of Thermal Injury Zones in the Superficial Musculoaponeurotic System Using Intense Ultrasound Therapy: A New Target for Noninvasive Facial Rejuvenation. *Archives of Facial Plastic Surgery*, **9**, 22-29. <https://doi.org/10.1001/archfaci.9.1.22>
- [17] Nipshagen, M.D., Velthuis, P.J. and Mosmuller, D.G.M. (2020) Periorbital Postinflammatory Hyperpigmentation after Plasma Exeresis. *Dermatology and Therapy*, **33**, e13404. <https://doi.org/10.1111/dth.13404>
- [18] Khan, U. and Khalid, N. (2021) A Systematic Review of the Clinical Efficacy of Micro-Focused Ultrasound Treatment for Skin Rejuvenation and Tightening. *Cureus*,

- 13, e20163. <https://doi.org/10.7759/cureus.20163>
- [19] Suh, D.H., Kim, D.H., Lim, H.K., Lee, S.J., Song, K.Y. and Kim, H.S. (2016) Intense Focused Ultrasound (IFUS) with a Modified Parameter on Facial Tightening: A Study on Its Safety and Efficacy. *Journal of Cosmetic and Laser Therapy*, **18**, 448-451. <https://doi.org/10.1080/14764172.2016.1225961>
- [20] Ko, E.J., Hong, J.Y., Kwon, T.R., Choi, E.J., Jang, Y.J., Choi, S.Y., Yoo, K.H., Kim, S.Y. and Kim, B.J. (2017) Efficacy and Safety of Non-Invasive Body Tightening with High-Intensity Focused Ultrasound (HIFU). *Skin Research and Technology*, **23**, 558-562. <https://doi.org/10.1111/srt.12371>
- [21] Oni, G., Hoxworth, R., Teotia, S., Brown, S. and Kenkel, J.M. (2014) Evaluation of a Microfocused Ultrasound System for Improving Skin Laxity and Tightening in the Lower Face. *Aesthetic Surgery Journal*, **34**, 1099-1110. <https://doi.org/10.1177/1090820X14541956>
- [22] Sasaki, G. and Tevez, A. (2012). Microfocused Ultrasound for Nonablative Skin and Subdermal Tightening to the Periorbitum and Body Sites: Preliminary Report on Eighty-Two Patients. *Journal of Cosmetics, Dermatological Sciences and Applications*, **2**, 108-116. <https://doi.org/10.4236/jcdsa.2012.222022>
- [23] Werschler, W.P. and Werschler, P.S. (2016) Long-Term Efficacy of Micro-Focused Ultrasound with Visualization for Lifting and Tightening Lax Facial and Neck Skin Using a Customized Vectorsing Treatment Method. *The Journal of Clinical and Aesthetic Dermatology*, **9**, 27-33.
- [24] Lee, H.S., Jang, W.S., Cha, Y.J., Choi, Y.H., Tak, Y., Hwang, E., Kim, B.J. and Kim, M.N. (2012) Multiple Pass Ultrasound Tightening of Skin Laxity of the Lower Face and Neck. *Dermatologic Surgery*, **38**, 20-27. <https://doi.org/10.1111/j.1524-4725.2011.02158.x>
- [25] Jeon, H., Kim, T., Kim, H. and Cho, S.B. (2018) Multimodal Approach for Treating Horizontal Neck Wrinkles Using Intensity Focused Ultrasound, Cohesive Polydensified Matrix Hyaluronic Acid, and IncobotulinumtoxinA. *Dermatologic Surgery*, **44**, 421-431. <https://doi.org/10.1097/DSS.0000000000001312>
- [26] Carruthers, J., Burgess, C., Dia, D., Fabi, S.G., Goldie, K., Kerschler, M., Nikolis, A., Pavicic, T., Rho, N.K., Rzany, B., Sattle, G., Sattler, S., Seo, K., Werschler, W.P. and Carruthers, A. (2016) Consensus Recommendations for Combined Aesthetic Interventions in the Face Using Botulinum Toxin, Fillers, and Energy-Based Devices. *Dermatologic Surgery*, **42**, 586-597. <https://doi.org/10.1097/DSS.0000000000000754>
- [27] Fabi, S.G., Goldman, M.P., Mills, D.C., Werschler, W.P., Green, J.B., Kaufman, J., Weiss, R.A. and Hornfeldt, C.S. (2016) Combining Microfocused Ultrasound with Botulinum Toxin and Temporary and Semi-Permanent Dermal Fillers: Safety and Current Use. *Dermatologic Surgery*, **42**, S168-S176. <https://doi.org/10.1097/DSS.0000000000000751>
- [28] Casabona, G. and Teixeira, D.N. (2018) Microfocused Ultrasound in Combination with Diluted Calcium Hydroxylapatite for Improving Skin Laxity and the Appearance of Lines in the Neck and Décolletage. *Journal of Cosmetic Dermatology*, **17**, 66-72. <https://doi.org/10.1111/jocd.12475>
- [29] Casabona, G. (2018) Combined Use of Microfocused Ultrasound and a Calcium Hydroxylapatite Dermal Filler for Treating Atrophic Acne Scars: A Pilot Study. *Journal of Cosmetic and Laser Therapy*, **20**, 301-306. <https://doi.org/10.1080/14764172.2017.1406606>
- [30] Ramirez, S. and Puah, I.B.K. (2021) Effectiveness of Combined Microfocused Ultrasound with Visualization and Subdermal Calcium Hydroxyapatite Injections for

- the Management of Brachial Skin Laxity. *Journal of Cosmetic Dermatology*, **20**, 3871-3879. <https://doi.org/10.1111/jocd.14573>
- [31] Park, J.Y., Byun, E.J. and Kim, H.S. (2020) Rejuvenation of Periocular Region in Koreans: A Multimodal Approach Combining Botulinum Toxin, Fillers, and Micro-Focused Ultrasound with Visualization for Optimal Results. *Dermatologic Therapy*, **33**, e13159. <https://doi.org/10.1111/dth.13159>
- [32] Friedmann, D., Fabi, S. and Goldman, M. (2014) Combination of Intense Pulsed Light, Sculptra, and Ultherapy for Treatment of the Aging Face. *Journal of Cosmetic Dermatology*, **13**, 109-118. <https://doi.org/10.1111/jocd.12093>