

# Tightening and Reduction of Unwanted Submental Fat Using Triple-Layer High-Intensity Focused Ultrasound: Clinical and 3-Dimensional Imaging Analysis

Hyuck Hoon Kwon, MD, PhD,\* Steven Hoseong Yang, MD, PhD,† Mira Choi, MD, MS,‡ Jae Yoon Jung, MD, MS,\* and Gyeong-Hun Park, MD, PhD§

**BACKGROUND** Unwanted submental fat (SMF) is aesthetically unappealing, but methods of reduction are either invasive or lack evidence of their use.

**OBJECTIVE** The authors sought to evaluate the safety and efficacy of a novel triple-layer high-intensity focused ultrasound (HIFU) regimen for SMF reduction.

**METHODS** Forty Korean subjects with moderate/severe SMF were evaluated after receiving a session of triple-layer HIFU treatments (using 3.0-, 4.5-, and 6.0-mm focusing transducers). The objective evaluation based on the 5-point Clinician-Reported Submental Fat Rating Scale (CR-SMFRS) and patients' satisfaction based on the 7-point Subject Self-Rating Scale (SSRS) were determined 8 weeks after treatment. Three-dimensional image analysis was also performed.

**RESULTS** At the follow-up visit, the proportion of treatment responders defined as subjects with  $\geq 1$ -point improvement in CR-SMFRS was 62.5%, and the proportion of patients satisfied with appearance of their face and chin (score  $\geq 4$  on the SSRS) was 67.5% of the total patients. The results of 3-dimensional analysis were consistent with clinical observations. Only mild and transient side effects were observed for some patients with no serious adverse effects.

**CONCLUSION** The triple-layer HIFU regimen including the novel 6.0-mm transducer has benefits for tightening and rejuvenation of the area with unwanted SMF, showing reasonable safety profiles.

Accumulation of subcutaneous fat in the preplatysmal area, undesirable submental fat (SMF), can lead to the loss of lower facial contour and mandibular definition.<sup>1</sup> This condition gives the appearance of obesity and aging, and it has been shown to contribute to negative aesthetic and psychological effects.<sup>2,3</sup> Although this cosmetic indication can be addressed surgically as part of platysmaplasty or liposuction,<sup>4</sup> patients' concerns regarding prolonged downtime and the invasive nature limit the popularity of these procedures. Therefore, nonsurgical energy devices, including cryolipolysis, radiofrequency, and high-intensity focused ultrasound (HIFU), and mesotherapy with deoxycholic acid or phosphatidylcholine have received much attention for dealing with these localized adipose tissues.<sup>5-7</sup>

High-intensity focused ultrasound has been widely applied as a novel treatment modality for skin tightening and

rejuvenation with superior safety profiles.<sup>8</sup> It produces small, microthermal lesions at precise depths up to the fibromuscular layer, causing thermally induced tissue contraction and coagulation with subsequent collagenesis.<sup>9,10</sup> Two conventional HIFU transducers (7 MHz, 3.0-mm focal depth and 4 MHz, 4.5-mm focal depth) have been used in the treatment of the face and neck, but a transducer with a lower frequency and deeper focal depth (2 MHz, 6.0 mm) also demonstrates satisfactory results for the treatment of skin and subcutaneous fat in certain body areas.<sup>11,12</sup>

Anatomically, SMF is a discrete areolar chamber residing within the preplatysmal fat bounded superficially by the dermis and deeply by the platysma.<sup>13,14</sup> Considering anatomic characteristics of SMF and lipolytic traits of a deeply penetrating transducer, the authors expected that the addition of a 6.0-mm transducer to the conventional treatment regimen could further contribute to reduction of subcutaneous fats and tightening of adjacent tissues. In this study, the authors evaluated the efficacy and safety of a triple-layer HIFU regimen including a novel 6.0-mm transducer for reduction of SMF by applying 3-dimensional (3D) analysis technology.

## Subjects and Methods

### Subjects

Forty Korean subjects completed this study (Table 1). Subjects were eligible to participate if they presented with moderate to severe SMF (Grade 2 or 3 on the 5-point Clinician-Reported Submental Fat Rating Scale [CR-SMFRS]) and expressed dissatisfaction with the appearance of their submental area

From the \*Oaro Dermatology Clinic, Seoul, Republic of Korea; †Guam Dermatology Institute, Guam; ‡Department of Dermatology, Ilsan Paik Hospital, Inje University College of Medicine, Goyang, Republic of Korea; §Department of Dermatology, Dongtan Sacred Heart Hospital, Hallym University College of Medicine, Hwaseong, Republic of Korea. The authors have indicated no significant interest with commercial supporters.

J. Y. Jung and G.-H. Park contributed equally as corresponding authors.

Address correspondence and reprint requests to: Gyeong-Hun Park, MD, PhD, Department of Dermatology, Dongtan Sacred Heart Hospital, Hallym University College of Medicine, 7, Keunjaebong-gil, Hwaseong-si, Gyeonggi-do 18450, Republic of Korea, or e-mail: borelalgebra@gmail.com

Supplemental digital content is available for this article. Direct URL citations appear in the printed text and are provided in the HTML and PDF versions of this article on the journal's Web site ([www.dermatologicsurgery.org](http://www.dermatologicsurgery.org)).

<http://dx.doi.org/10.1097/DSS.0000000000003241>

Downloaded from http://journals.lww.com/dermatologicsurgery by BNDMSEPHKAVTZEUMT1QIN4a+kLhEZgbsIH on 03/29/2023

(Subject Self-Rating Scale [SSRS] score 0 to 3) (See **Supplemental Digital Content 1**, Table S1, <http://links.lww.com/DSS/A916>).<sup>15</sup> Key exclusion criteria included pregnancy, a history of keloidal scarring, and cosmetic surgery or rejuvenation procedures within 6 months before the study. Patients with a body mass index >35 kg/m<sup>2</sup> and those undergoing or considering a weight reduction program were also excluded. All patients were informed of the benefits, risks, and possible complications of the treatment before enrolment, and informed consent was obtained from each participant. Protocol of this study conformed to the ethical guidelines of the Declaration of Helsinki (1975) and was approved by the Institutional Review Board.

### Treatment Protocol

One HIFU device (Shurink/Ultraformer; Classys, Inc., Seoul, Korea) was used in this study. The authors used 3 different types of transducers (T2: 3.0-mm focal depth, T3: 4.5-mm focal depth, and T4: 6.0-mm focal depth). Each transducer delivered a series of ultrasound pulses along 25-mm-long exposure lines. The pulse duration for each individual exposure ranged from 25 to 40 milliseconds.

All patients received one designated session of HIFU. Before treatment, submental areas were cleansed with a mild soap, and topical anesthesia with EMLA (Astrazeneca, Södertälje, Sweden) was applied to the SMF under 30-minute occlusion. After gently removing the anesthetic cream, ultrasound gel was applied to the skin. The probe was then placed firmly on the skin surface with uniform pressure. To avoid possible damage to the marginal mandibular nerve, the space within 1.0 cm along the mandibular borderline was spared from treatment. Submental fat was treated with 80 lines of 6.0-mm probe at an energy setting of 0.8 to 1.0 J, immediately followed by 60 lines of 4.5-mm probe at 0.5 to 0.7 J, then finally by 60 lines of 3.0-mm probe at 0.3 to 0.5 J (Figure 1). The spacing of pulses within each linear array was set parallel at 1.5–2.0 mm. On average, a total of 200 lines to the SMF were delivered. The treated areas were then soothed by cooling packs for 10 minutes. After finishing the protocol, 33 subjects were reinterviewed by phone or email. They were asked about their SMF status 6 to 8 months after the

procedure. In addition, 1 participant visited again and took pictures under the same conditions.

### Outcome Evaluations

Follow-up visits took place 8 weeks after the treatment session. Improvement was defined as the proportion of treatment responders, that is, with a reduction in SMF of ≥1 point on the 5-point CR-SMFRS compared with baseline, and the proportion of patients satisfied with their appearance in association with their face and chin (i.e., with a score of ≥4 on the 7-point SSRS rating scale). Clinician-Reported Submental Fat Rating Scale was determined by 2 dermatologists evaluating paired baseline and follow-up photographs of the 40 patients in a randomized fashion. Photographic documentation using the same camera settings (EOS 600D; Canon, Tokyo, Japan) and lighting conditions was obtained at each visit. Pain sensation during treatments was reported using a 0-to-10 visual analogue scale (VAS) score (0: none; 10: extremely severe).<sup>16</sup> Treatment-related adverse effects were characterized descriptively at each visit.

### Three-Dimensional Measurement

To provide supportive data for the objective evaluation of treatment results, a 3D camera and software (Morpheus Co., Ltd., Seongnam, Gyeonggi-do, Korea) were used for 20 patients. Images taken were imported into Mirror Analysis 3D software and registered using anatomical landmarks for proper alignment. Topographical changes gained after superimposition of multiple pictures provided complementary data. Surface area reduction of SMF was also measured on 3D photographs.

## Results

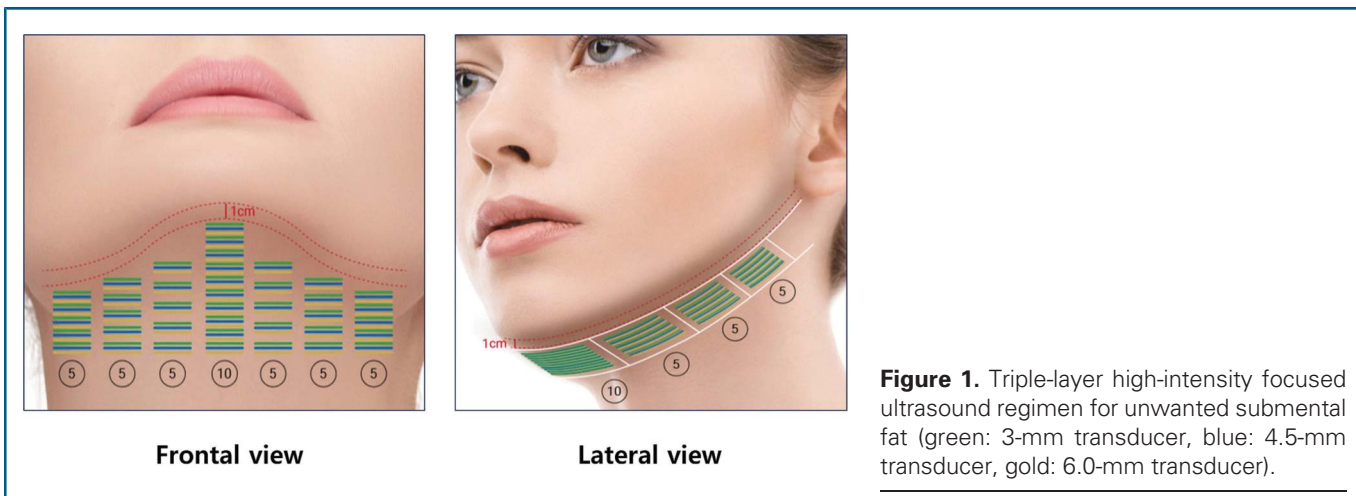
### Clinical Efficacy

At the follow-up visit, the proportion of treatment responders (≥1 point improvement in the 5-point CR-SMFRS) based on objective evaluation was 62.5% (25/40) of all enrolled patients. Ten patients (25.0%) experienced more remarkable improvement (≥2-point improvement in CR-SMFRS) only with a single HIFU session. The proportion of patients satisfied with the appearance of their

**TABLE 1. Demographic and Baseline Characteristics**

	Subjects, n = 40
Age, mean (SD), yr	40.5 (11.0)
Female, n (%)	38 (95.0)
Race	All Korean patients
BMI, mean (SD), kg/m <sup>2</sup>	23.8 (3.2)
SMF grade by CR-SMFRS, n (%)	Grade 2: 16 (40%), Grade 3: 24 (60%)
Fitzpatrick skin type, n (%)	III: 15 (37.5%), IV: 20 (50.0%), V: 5 (12.5%)

BMI, body mass index; CR-SMFRS, Clinician-Reported Submental Fat Rating Scale; SMF, submental fat.



**Figure 1.** Triple-layer high-intensity focused ultrasound regimen for unwanted submental fat (green: 3-mm transducer, blue: 4.5-mm transducer, gold: 6.0-mm transducer).

face and chin after treatment (score  $\geq 4$  on the 7-point SSRS) was 67.5% (27/40) of all enrolled patients. Photographs of representative patients treated with the triple-layer technique of HIFU are shown in Figures 2 and 3. Lateral views clearly demonstrated that cervicomental angles decreased remarkably after HIFU treatments. At 6 to 8 months after the procedure, 33 subjects were interviewed again by phone or email. Most of them (73%) replied that their SMF status remained improved compared with baseline.

**Three-Dimensional Image Data Analysis**

The volume map of a fusion of 3D images before and after treatment further validated the volume loss of SMF as a result of skin tightening and lipolysis (Figure 4). In all 20 patients participating in 3D image analysis, topographical changes and designated area maps indicated a decrease in

SMF to varying degrees. Topographical color maps commonly showed that the lower part of SMF decreased more than the upper part. On average,  $7.7\% \pm 1.7\%$  (mean  $\pm$  SE) of SMF surface area was decreased after one session of HIFU treatment.

**Safety Profiles**

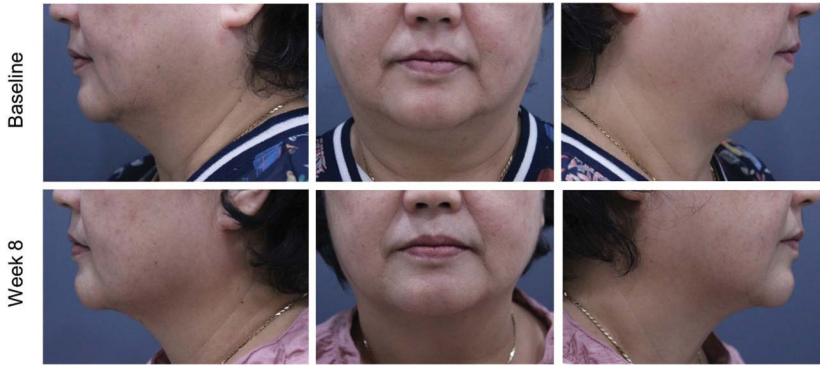During treatments, patients felt only minimal pain, with an average VAS of 3.3. No patient reported severe pain requiring oral medication for analgesia or sedation. Eleven patients (27.5%) had mild erythema that persisted less than 1 day. Other mild posttreatment signs also disappeared soon after. There were no serious adverse events such as persistent scar, bruising, or prolonged numbness. Detailed information on safety profiles is described in Table 2. All patients were able to return to their usual activity just after treatment.

32-year-old female patient

	Weight (kg)	CRSMFRS	SSRS
Baseline	58.3	3	1
Week 27	57.9	1	6

**Figure 2.** A 32-year-old woman treated with one session of triple-layer high-intensity focused ultrasound regimen for her unwanted submental fat. CR-SMFRS, Clinician-Reported Submental Fat Rating Scale; SSRS, Subject Self-Rating Scale.

63-year-old female patient



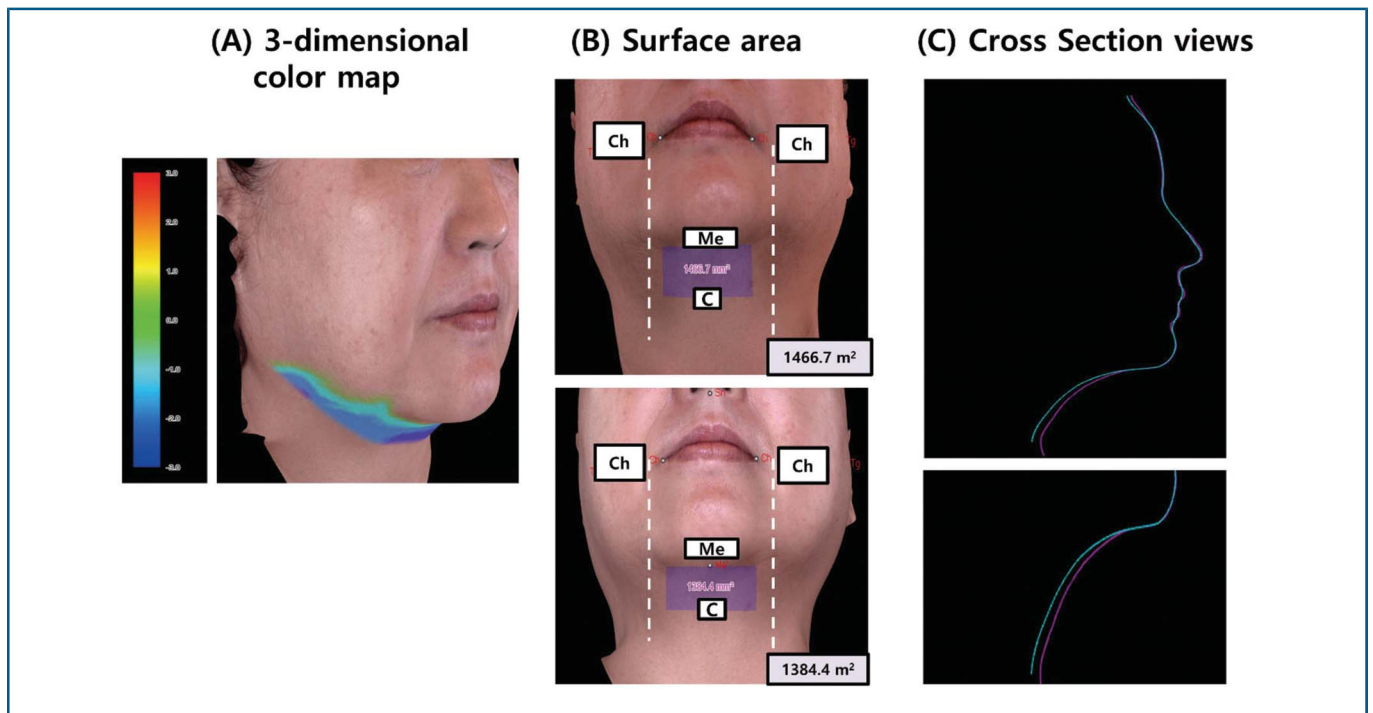
	Weight (kg)	CRSMFRS	SSRS
Baseline	65.3	3	1
Week 8	65.1	2	5

**Figure 3.** A 63-year-old woman treated with one session of triple-layer high-intensity focused ultrasound regimen for her unwanted submental fat. CR-SMFRS, Clinician-Reported Submental Fat Rating Scale; SSRS, Subject Self-Rating Scale.

## Discussion

The number of noninvasive procedures is constantly growing in cosmetic dermatology. Compared with other devices or mesotherapies, HIFU demonstrates superiority in safety profile since it provides focused ultrasonic ablation energy only to the designated depth without affecting adjacent tissues.<sup>8,17</sup> Although unwanted SMF is

a major aesthetic concern, conventional HIFU transducers may not fully cover the deeply located preplatysmal fat. Considering that deeper-depth focusing transducers effectively reduce subcutaneous body fat, the authors applied the novel triple-layer HIFU regimen including a 6.0-mm transducer for the treatment of unwanted SMF.



**Figure 4.** Three-dimensional image analysis before and after a high-intensity focused ultrasound (HIFU) treatment session. (A) In the superimposed image views, topographical changes in the baseline picture compared with that of the follow-up visit are colored. As dictated in the diagram, yellow indicates areas where the vertical height of the skin surface was increased compared with baseline image, and blue indicates areas where the height was lower, which indicates a decrease in submental fat. (B) Submental surface area designated by the rectangle surrounded by vertical lines of 2 cheilion (Ch) points and horizontal lines of soft tissue menton (Me) and cervical (C) points. (C) Cross-sectional views of a patient's face before (purple) and after (blue) HIFU treatments.

Downloaded from http://journals.lww.com/dermatologicsurgery by BNDMSEPHKAV1ZEU0M1QIN4a+kLLHEZgbsIH 04XMI0hCwCk1AVWnYQpI0IH3D3D00dF5y7TVSFIACI3V/C4/OAV/DPD3a8K2+Y36H515KE= on 03/29/2023

TABLE 2. Summary of Adverse Events	
Adverse Events	Patients, n (%)
Pain	3.3 ± 1.3*
Erythema	11 (27.5%)
Edema	5 (12.5%)
Pruritus	3 (7.5%)
Skin tightness	8 (20%)
Other serious adverse effects	0 (0%)
* Mean ± SD.	

The results of this study demonstrated satisfactory efficacy of this triple-layer regimen for SMF. More than 60% of the enrolled patients subjected to only a single session showed improvements from the perspectives of investigator-reported and patient-reported evaluations, which was consistent with the results of 3D image analyses. These results strongly suggest that this technique is at least comparable with other conventional devices or injections for the treatment of SMF.<sup>5-7,15,18</sup> The safety profile demonstrated only slight and transient posttreatment side effects and mild pain for most patients, which supports the superior advantages of HIFU compared with other treatment approaches.<sup>5-7,15,18</sup> There was no serious complication such as skin blistering or purpura as a consequence of wave reflection by HIFU.

In addition to the tightening effects of conventional regimens, the novel 6.0-mm transducer may further consolidate the reduction of the subcutaneous layer around SMF based on clinical observation. The mechanism for HIFU-based fat reduction has been demonstrated to involve both mechanical and thermal effects.<sup>19,20</sup> At early time points, HIFU disrupts adipocytes mechanically by forming bubbles in the cells. Histologically, ultrasound destroys adipocytes selectively, leaving connective tissue, blood vessels, or nerves intact. Meanwhile, the controlled thermal effect of HIFU seems to provide precise and safe means for the removal of fatty tissues. The heat from the absorbed ultrasound energy triggers liquefaction and disruption of the membrane of adipocytes.<sup>21,22</sup> The mechanical and thermal effects can occur together, and the mechanical activity enhances local heat deposition.<sup>23</sup>

In this study, instances of marginal mandibular nerve (MMN) paresis were not observed. The anatomical course of the MMN is variable and runs both inferior and superior to the mandibular border.<sup>24</sup> Posterior to the antegonial notch, the MMN courses inferior to the mandible. Anterior to this bony landmark (at the anterior portion of the masseter muscle), the MMN courses superficially over the mandible to innervate the lip depressors.<sup>25</sup> To prevent possible MMN injury, the authors applied the transducers beneath the line drawn 1.0 cm below the inferior mandibular border.

Topographical changes measured by 3D images establish changes in the surface areas over time, demonstrating the impact on the tissue that could potentially be related to reduced skin laxity.<sup>26-28</sup> One important issue in cosmetic dermatology is the paucity of objective evaluation methods. Although craniofacial anthropometry and 2-dimensional photographs have been used, they have some limitations in clinical practicability and detection of volume changes.<sup>29</sup> The introduction of 3D imaging software has advanced abilities to quantify both volume and surface area reduction in detail, allowing spatial analysis of numerous “facial contour rejuvenating” procedures. More quantitative measurements designed for tightening and reduction of the submental area with designated criteria based on a large clinical database would be required in the future studies.

There are some limitations in this study. First, all enrolled subjects were of identical ethnic origin. Second, further studies will be needed on the optimal parameters for each transducer and total number of treatment sessions. Third, the duration of follow-up observation was rather short. Although some of the patients have reported the long-term status, it would be more desirable to check the results for all patients 12 months after treatment. Finally, a comparative study with other devices or placebo will be useful because scoring may be favorably biased in single-arm studies.

On the basis of these findings, the authors conclude that the triple-layer HIFU regimen including a novel 6.0-mm transducer has benefits for the tightening and rejuvenation of the SMF area with reasonable safety profiles. Thus, this therapeutic regimen could be a viable option for SMF treatment in the Asian population.

### References

- Rohrich RJ, Rios JL, Smith PD, Gutowski KA. Neck rejuvenation revisited. *Plast Reconstr Surg* 2006;118:1251-63.
- Co AC, Abad-Casintahan MF, Espinoza-Thaebtharm A. Submental fat reduction by mesotherapy using phosphatidylcholine alone vs. phosphatidylcholine and organic silicium: a pilot study. *J Cosmet Dermatol* 2007;6:250-7.
- Rzany B, Carruthers A, Carruthers J, Flynn TC, et al. Validated composite assessment scales for the global face. *Dermatol Surg* 2012;38:294-308.
- Koehler J. Complications of neck liposuction and submentoplasty. *Oral Maxillofac Surg Clin North Am* 2009;21:43-52, vi.
- Rzany B, Griffiths T, Walker P, Lippert S, et al. Reduction of unwanted submental fat with ATX-101 (deoxycholic acid), an adipocytolytic injectable treatment: results from a phase III, randomized, placebo-controlled study. *Br J Dermatol* 2014;170:445-53.
- Leal Silva H, Carmona Hernandez E, Grijalva Vazquez M, Leal Delgado S, et al. Noninvasive submental fat reduction using colder cryolipolysis. *J Cosmet Dermatol* 2017;16:460-5.
- Nelson AA, Wasserman D, Avram MM. Cryolipolysis for reduction of excess adipose tissue. *Semin Cutan Med Surg* 2009;28:244-9.
- Laubach HJ, Makin IR, Barthe PG, Slayton MH, et al. Intense focused ultrasound: evaluation of a new treatment modality for precise microcoagulation within the skin. *Dermatol Surg* 2008;34:727-34.
- Kwon HH, Lee WY, Choi SC, Jung JY, et al. Combined treatment for skin laxity of the aging face with monopolar radiofrequency and intense focused ultrasound in Korean subjects. *J Cosmet Laser Ther* 2018;20:449-53.
- Kwon HH, Choi SC, Park KH, Jung JY. A novel combination regimen with intense focused ultrasound and pressure- and dose-controlled transcutaneous pneumatic injection of hypertonic glucose solution for

lifting and tightening of the aging face. *J Cosmet Dermatol* 2018;17:373–9.

11. Choi SY, No YA, Kim SY, Kim BJ, et al. Tightening effects of high-intensity focused ultrasound on body skin and subdermal tissue: a pilot study. *J Eur Acad Dermatol Venereol* 2016;30:1599–602.
12. Oni G, Hoxworth R, Teotia S, Brown S, et al. Evaluation of a microfocused ultrasound system for improving skin laxity and tightening in the lower face. *Aesthet Surg J* 2014;34:1099–110.
13. Labbe D, Giot JP, Kaluzinski E. Submental area rejuvenation by di-gastric corset: anatomical study and clinical application in 20 cases. *Aesthet Plast Surg* 2013;37:222–31.
14. Hatef DA, Koshy JC, Sandoval SE, Echo AP, et al. The submental fat compartment of the neck. *Semin Plast Surg* 2009;23:288–91.
15. Humphrey S, Sykes J, Kantor J, Bertucci V, et al. ATX-101 for reduction of submental fat: a phase III randomized controlled trial. *J Am Acad Dermatol* 2016;75:788–97.
16. Jung HJ, Min J, Seo HM, Kim WS. Comparison of effect between high intense focused ultrasound devices for facial tightening: evaluator-blinded, split-face study. *J Cosmet Laser Ther* 2016;18:252–6.
17. White WM, Makin IR, Barthe PG, Slayton MH, et al. Selective creation of thermal injury zones in the superficial musculoaponeurotic system using intense ultrasound therapy: a new target for noninvasive facial rejuvenation. *Arch Facial Plast Surg* 2007;9:22–9.
18. Ascher B, Hoffmann K, Walker P, Lippert S, et al. Efficacy, patient-reported outcomes and safety profile of ATX-101 (deoxycholic acid), an injectable drug for the reduction of unwanted submental fat: results from a phase III, randomized, placebo-controlled study. *J Eur Acad Dermatol Venereol* 2014;28:1707–15.
19. Brujan EA. Shock wave emission from laser-induced cavitation bubbles in polymer solutions. *Ultrasonics* 2008;48:423–6.
20. Brown SA, Greenbaum L, Shtukmaster S, Zadok Y, et al. Characterization of nonthermal focused ultrasound for noninvasive selective fat cell disruption (lysis): technical and preclinical assessment. *Plast Reconstr Surg* 2009;124:92–101.
21. Gadsden E, Aguilar MT, Smoller BR, Jewell ML. Evaluation of a novel high-intensity focused ultrasound device for ablating subcutaneous adipose tissue for noninvasive body contouring: safety studies in human volunteers. *Aesthet Surg J* 2011;31:401–10.
22. Jewell ML, Desilets C, Smoller BR. Evaluation of a novel high-intensity focused ultrasound device: preclinical studies in a porcine model. *Aesthet Surg J* 2011;31:429–34.
23. Kyriakou Z, Corral-Baques MI, Amat A, Coussios CC. HIFU-induced cavitation and heating in ex vivo porcine subcutaneous fat. *Ultrasound Med Biol* 2011;37:568–79.
24. Dingman RO, Grabb WC. Surgical anatomy of the mandibular ramus of the facial nerve based on the dissection of 100 facial halves. *Plast Reconstr Surg Transpl Bull* 1962;29:266–72.
25. Hazani R, Chowdhry S, Mowlavi A, Wilhelmi BJ. Bony anatomic landmarks to avoid injury to the marginal mandibular nerve. *Aesthet Surg J* 2011;31:286–9.
26. Graham PM, McDaniel DH, DaSilva D, Canfield D, et al. Use of 3-dimensional imaging in submental fat reduction following hyper-thermic laser lipolysis. *Dermatol Surg* 2019;45:988–91.
27. Li MK, Mazur C, DaSilva D, Canfield D, et al. Use of 3-dimensional imaging in submental fat reduction after cryolipolysis. *Dermatol Surg* 2018;44:889–92.
28. Li MK, Mazur C, McDaniel DH, DaSilva D, et al. Use of 3-dimensional imaging in submental fat reduction after deoxycholic acid injection. *Dermatol Surg* 2018;44:599–602.
29. Weinberg SM, Naidoo S, Govier DP, Martin RA, et al. Anthropometric precision and accuracy of digital three-dimensional photogrammetry: comparing the Genex and 3dMD imaging systems with one another and with direct anthropometry. *J Craniofac Surg* 2006;17:477–83.