

## SHORT REPORT

# Tightening effects of high-intensity focused ultrasound on body skin and subdermal tissue: a pilot study

S.Y. Choi,<sup>1</sup> Y.A. No,<sup>1</sup> S.Y. Kim,<sup>2</sup> B.J. Kim,<sup>1,\*</sup> M.N. Kim<sup>1</sup><sup>1</sup>Department of Dermatology, Chung-Ang University College of Medicine, Seoul, South Korea<sup>2</sup>Department of Applied Statistics, Chung-Ang University, Seoul, South Korea

\*Correspondence: B.J. Kim. E-mail: beomjoon@unitel.co.kr

## Abstract

**Background** High-intensity focused ultrasound (HIFU) has been introduced as a new treatment modality for skin tightening through application mainly to the face and neck.

**Objectives** This pilot study assessed the efficacy and safety of HIFU for body tightening in Asian females.

**Methods** Six Asian female adults were enrolled in this pilot study. All subjects were treated with HIFU to the both cheek, upper arm, lower abdomen, thigh and calf using the following probes: 7 MHz, 1.5 mm focal depth; 2 MHz, 3.0 mm focal depth; 2 MHz, 4.5 mm focal depth; 2 MHz, 6.0 mm focal depth and 2 MHz, 9.0 mm focal depth. Three blinded independent dermatologists assessed results using the Investigator Global Aesthetic Improvement Scale (GAIS) using paired pre- and post-treatment (week 4) standardized photographs. Also, we evaluated skin elasticity at all treated sites using a cutometer. Participants used the subject GAIS to assess their clinical improvement after treatment and rated their pain using a visual analogue scale (VAS) immediately, 1 and 4 weeks after treatment.

**Results** The three blinded evaluators judged all treated sites as showing clinical improvement 4 weeks after treatment. Skin elasticity measured via cutometer was significantly improved 4 weeks after treatment at all treated sites ( $P < 0.05$ ). All patients scored themselves subjectively as more than 'improved' on the GAIS. Immediately after treatment the mean VAS score was  $5.17 \pm 2.48$ , but no pain was reported at weeks 1 and 4. No permanent adverse effects were observed during the follow-up period.

**Conclusion** For body tightening, we applied HIFU using transducers with a lower frequency and deep focal depth to effectively deliver ultrasound energy to skin tissues. HIFU appears to be a safe and effective treatment modality for dermal and subdermal tightening.

Received: 29 October 2015; Accepted: 15 March 2016

## Conflicts of interest

None declared.

## Funding sources

None declared.

## Introduction

As skin tissue ages, its elasticity decreases and redundant facial, neck and body laxity are commonly seen. Various treatment modalities including surgical, laser and radiofrequency approaches have been used to improve skin laxity. Surgical lifting procedures for skin laxity are effective, but can leave visible surgical scars and are associated with risk and lengthy recovery times. Recently, patients seeking skin tightening are requesting safe and effective non-invasive alternatives associated with low risks and minimal downtime.

High-intensity focused ultrasound (HIFU) has been investigated as a tool for the treatment of solid benign and malignant tumours for the past several decades.<sup>1</sup> HIFU can produce small, micro-thermal lesions at precise depths in the dermis up to the

fibromuscular layer, causing thermally induced contraction of collagen and tissue coagulation with subsequent collagenesis, while sparing the epidermis.<sup>2–4</sup> Recently, HIFU has been introduced as a new treatment modality for skin tightening and rejuvenation, primarily for the face and neck.<sup>5</sup> This pilot study was performed to assess the efficacy and safety of HIFU treatment for skin tightening treatment of body skin laxity in Asian females.

## Patients and methods

### Patients

This pilot study was approved by the Institutional Review Board of Chung-Ang University Hospital and followed the guidelines

of the 1975 Declaration of Helsinki. Based on the suggestion of a statistical committee, we referred to a previous study<sup>6</sup> to determine the number of subjects required for the current study. Six female adults were enrolled in the study.

### HIFU device

The HIFU device used in this study was the ULTRAFORMER III, SHURINK (CLASSYS INC., Seoul, Korea). In this study, we used five different types of transducers. One of the transducers was a basic transducer for facial skin tightening (T1: 7 MHz, 1.5 mm focal depth). Four other transducers utilizing a lower frequency and deeper focal depths were newly developed for body skin tightening (T2: 2 MHz, 3.0 mm focal depth, T3: 2 MHz, 4.5 mm focal depth, T4: 2 MHz, 6.0 mm focal depth and T5: 2 MHz, 9.0 mm focal depth). Each transducer delivered a series of ultrasound pulses along 25-mm long exposure lines. The pulse duration for each individual exposure ranged from 25 to 40 milliseconds.

### Treatment procedures

Before treatment, we checked the patients, the thickness of skin components and all patients underwent treatment in five different areas including the both cheek, upper arm, lower abdomen, thigh and calf after topical anaesthetic cream. The sizes of the treated areas were  $5.0 \times 5.0 \text{ cm}^2$  on each cheek and  $7.5 \times 7.5 \text{ cm}^2$  on the lower abdomen as well as each upper arm, thigh and calf (Fig. 1).

Ultrasound gel was applied to the treated skin and the transducer was pressed perpendicularly, uniformly and firmly to the skin surface. Treatment exposure was initiated with a line of individual ultrasound pulses being delivered over approximately 2 s. Next, the probe was moved approximately 3 to 5 mm laterally so as to be parallel and adjacent to the line previously treated and the ultrasonic exposure was repeated.

Each side of the face was treated with three types of transducers (T1, T2 and T3), distributing a total of 552.5 J. Each side of the body was treated with five types of transducers (T1, T2, T3,

T4 and T5), distributing a total of 817.2 J. We operated the powers with 1.0–1.5 J at each transducer. When patient feel pain, we reduced 0.1–0.3 J per time, but not increased up to 1.5 J.

Complete HIFU treatment of the face and body occurred over 50–60 min. We prefer to use the shallow depth tips to deep depth tips. Because patient's pains are usually proportional to depth of tips.

### Efficacy and pain evaluation

We evaluated the skin tightening effect of HIFU using photography and a cutometer. The investigator gathered digital photographs using identical cameras and camera settings (Canon EOS 600D, high-resolution setting,  $5760 \times 3840$  pixels, Canon Inc., Tokyo, Japan) before and 4 weeks after the treatment. Three blinded independent dermatologists evaluated paired before and after photographs in a randomized fashion using the Investigator Global Aesthetic Improvement Scale (IGAIS). Subjects assessed the tightening effects using the Subject Global Aesthetic Improvement Scale (SGAIS) 4 weeks after treatment.

The Cutometer<sup>®</sup> (Courage+Khazaka Electronic GmbH, Cologne, Germany) was used to measure skin elasticity. Among the cutometer-specific *R* values (R0–R9), we used the R7 value, which is defined as the ratio of elastic recovery to the total deformation and represents the biological elasticity.

Pain was evaluated by visual analogue scale (VAS) immediately after week 0 and on weeks 1 and 4 after the application of HIFU. VAS is a simple and reproducible tool for the assessment of pain severity which consisted of 11 levels (0–10 points).

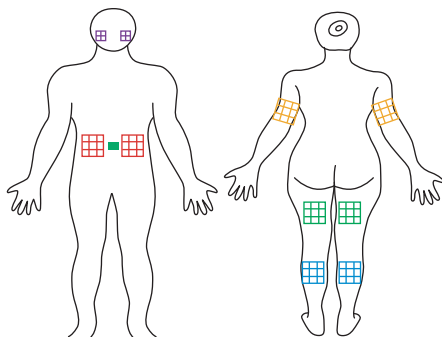
### Statistical analysis

Statistical analyses were performed using SPSS version 18.0 for Windows (SPSS Inc., Chicago, IL). We used Hochberg step-up methods to adjust the values for multiple comparisons. Statistical comparisons between before and after treatments were performed using paired *t* tests. Data are presented as means  $\pm$  standard deviation. *P*s < 0.05 were considered statistically significant.

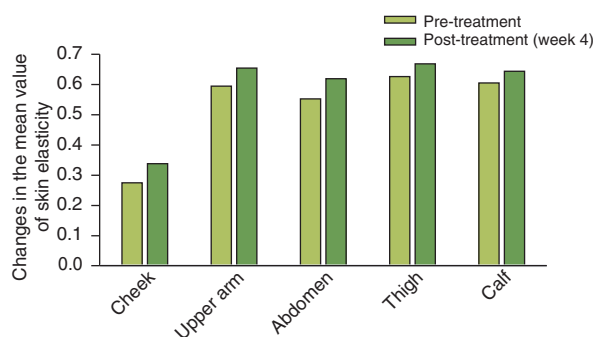
### Results

Six Asian female subjects (Fitzpatrick skin types III–V) with skin laxity were enrolled in this study. Their ages ranged from 43 to 54 years (mean  $\pm$  SD:  $48.17 \pm 4.45$  years) and showed similar skin depth. All subjects completed the HIFU treatments and follow-up for 4 weeks.

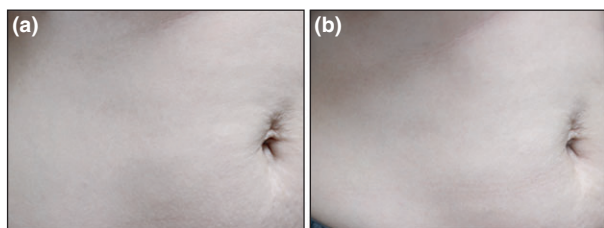
The mean value of skin elasticity measured by cutometer was significantly increased at 4 weeks after treatment compared to baseline in all treated sites on the face and body (Fig. 2). The change in the mean value of skin elasticity measured by cutometer was greatest in the lower abdomen (Fig. 3).



**Figure 1** Face and body treatment areas.



**Figure 2** Changes in the mean value of skin elasticity measured via cutometer (R7, mean  $\pm$  SD).



**Figure 3** The change in the skin elasticity in the lower abdomen (a) 0 week and (b) after 4 weeks.

Three blinded independent dermatologists judged all patients as showing clinical improvement 4 weeks after treatment. In terms of cheek outcomes, 5 (83.3%) of 6 subjects were assessed as improved (IGAIS score 1), and 1 (16.7%) of 6 subjects as much improved (IGAIS score 2). In terms of body outcomes, including the upper arm, lower abdomen, thigh and calf, 6 (100%) of 6 subjects were assessed as improved (IGAIS score 1).

All subjects scored the SGAIS as more than score 1 in all treated sites. The mean SGIAS score in the calf was the highest. In the calf, 2 (33.3%) of 6 subjects were assessed as improved (SGAIS score 1), 2 (33.3%) of 6 subjects as much improved (SGAIS score 2) and 2 of (33.3%) 6 subjects as very much improved (SGAIS score 3).

We evaluated pain using the VAS immediately after treatment (week 0) and at weeks 1 and 4. Immediately after treatment, the mean VAS score was  $5.17 \pm 2.48$  (range: 3–8). Three (50%) of six subjects rated their pain as mild, and 3 of (50%) 6 subjects rated their pain as moderate. One and 4 weeks after treatment, all subjects reported a VAS score of 0 (no pain).

One subject experienced oedema on the right upper arm and one subject had muscle pain on the right calf after HIFU treatment. Both oedema and muscle pain were mild and transient, and resolved within 1 week without any treatment. There were no serious or delayed adverse effects during the follow-up period.

## Discussion

Recently, minimally invasive or non-invasive procedures have been gradually replacing surgical intervention in cosmetic dermatology. For the treatment of skin laxity, non-invasive, non-ablative thermal therapeutic devices can immediately denature collagen fibres and contract collagen fibres in the dermis and subcutaneous tissues and induce delayed neocollagenesis and elastogenesis.<sup>7,8</sup> Radiofrequency, infra-red light sources and HIFU have shown clinical effects for skin tightening and rejuvenation on the face and neck. However, there have been fewer clinical trials or reports of skin and subdermal tightening effects of non-ablative thermal devices in sites on the body, compared to the face and neck.

In this pilot study, we sought to assess the efficacy and safety of HIFU treatments using transducers that were newly developed to be suitable for use on the body skin and subdermal tissue for the purpose of skin tightening in body laxity in Asian people. A previous clinical report on the effects of HIFU on tightening of the periorbitum and body sites, which enrolled a total of 82 patients including 8 Asians, has been published. However, this previous clinical study used conventional HIFU transducers (10 MHz, 1.5 mm focal depth; 7 MHz, 3.0 mm focal depth and 4 MHz, 4.5 mm focal depth). We applied newly developed transducers to body sites with a lower frequency (2 MHz) and deeper focal depths (3.0–9.0 mm) compared with conventional transducers. Therefore, we expected that newly developed transducers could effectively deliver HIFU energy deeper into the skin and subdermal tissues of the body and show tightening effects and safety. Of course, it may effect to subcutaneous areas with 9.0 mm transducer. But it can reduce subcutaneous fats and lead to skin rejuvenation. Also, other reports said that if practitioner consider skin depths and regulate transducers well, 1.1–1.6 mm transducers are safe to use.<sup>9</sup>

Although we applied topical anaesthetic cream on treated sites, most subjects complained of a mild to moderate degree of pain during treatment in proportion to depth or power of transducers. Their pain subsided without the use of analgesics, but the injection of small amounts of local anaesthesia into the subcutaneous tissue should be considered for pain reduction.

In conclusion, HIFU treatment using transducers with a lower frequency and greater focal depth could be an effective and safe treatment modality for skin and subdermal tightening of the body. The limitations of this pilot study were the small number of subjects and the short-term follow-up period. Based on the results of this pilot study, well-designed controlled clinical studies with greater subject enrolment and long-term follow-up will be necessary to establish optimal treatment parameters.

## References

- 1 Laubach HJ, Makin IR, Barthe PG *et al*. Intense focused ultrasound: evaluation of a new treatment modality for precise microcoagulation within the skin. *Dermatol Surg* 2008; **34**: 727–734.

- 2 Alam M, White LE, Marin N *et al.* Ultrasound tightening of facial and neck skin: a rater-blinded prospective cohort study. *J Am Acad Dermatol* 2010; **62**: 262–269.
- 3 Suh DH, Shin MK, Lee SJ *et al.* Intense focused ultrasound tightening in Asian skin: clinical and pathologic results. *Dermatol Surg* 2011; **37**: 1595–1602.
- 4 Lee HS, Jang WS, Cha YJ *et al.* Multiple pass ultrasound tightening of skin laxity of the lower face and neck. *Dermatol Surg* 2012; **38**: 20–27.
- 5 Lee HJ, Lee KR, Park JY *et al.* The efficacy and safety of intense focused ultrasound in the treatment of enlarged facial pores in Asian skin. *J Dermatol Treat* 2015; **26**: 73–77.
- 6 DiBernardo BE, Evaluation of skin tightening after laser-assisted liposuction. *Aesthet Surg J.* 2009;**29**:400–407.
- 7 Chua SH, Ang P, Khoo LS *et al.* Nonablative infrared skin tightening in Type IV to V Asian skin: a prospective clinical study. *Dermatol Surg* 2007; **33**: 146–151.
- 8 Hantash BM, Ubeid AA, Chang H *et al.* Bipolar fractional radiofrequency treatment induces neoelastogenesis and neocollagenesis. *Laser Surg Med* 2009; **41**: 1–9.
- 9 Solish N, Lin X, Axford-Gatley RA *et al.* A Randomized, Single-Blind, Post-marketing Study of Multiple Energy Levels of High-Intensity Focused Ultrasound for Noninvasive Body Sculpting. *Dermatol Surg* 2012; **38**:58–67.