

## Evaluation of Micro-focused Ultrasound for Lifting and Tightening the Face

In Ho Lee et al. | South Korea

**Background** Micro-focused ultrasound (MFU) has developed as an effective, noninvasive, skin-tightening method. However, certain factors have limited its replacement of invasive surgical procedures, including a relative lack of efficacy, persistence, and reliability. The purpose of this study was to evaluate the efficacy and safety of MFU for noninvasive skin tightening and to determine how long the skin tightening can be maintained.

**Methods** Between October 2013 and November 2014, 41 patients with sagging and laxity of the facial skin were treated with MFU. The treatment was performed following the manufacturer's recommended protocol that called for 300 treatment lines. We evaluated the patients using an automatic skin diagnosis system at pretreatment, and 2 and 4 months after treatment.

**Results** Of the 41 patients treated using MFU, 3 patients were lost to follow-up for nonstudy-related reasons. In our study, 38 patients (1 male and 37 female) were evaluated and ranged in age from 37 to 52 years. The median skin grade scores were 5 at pre-treatment, 3 at 2 months post-treatment and 3 at 4 months post-treatment. After comparing pre-treatment and 2 months post-treatment, pre-treatment and 4 months post-treatment, and both 2 and 4 months post-treatment, there were statistically significant differences ( $P < 0.01$ ).

**Conclusions** This study suggests that the aging face, with wrinkling and sagging, can be improved using MFU, while minimizing injury to the epidermis and dermis.

**Keywords** Micro-focused Ultrasound, Aging face, Lifting

### INTRODUCTION

Received: May 13, 2015 Revised: May 27, 2015 Accepted: May 27, 2015

Correspondence: Seung Min Nam Department of Plastic and Reconstructive, Soonchunhyang University Bucheon Hospital, 170 Jomaru-ro, Wonmi-gu, Bucheon 420-767, Korea. E-mail: zodiac1003@naver.com

Copyright © 2015 The Korean Society for Aesthetic Plastic Surgery. This is an Open Access article distributed under the terms of the Creative Commons Attribution Non-Commercial

The signs of aged facial skin are not only fine lines and surface irregularities, but also sagging and wrinkling [1]. Noninvasive skin tightening is superior to invasive or surgical skin tightening in terms of rapid return to work, short recovery time, and low risk of adverse events. Because of these advantages, patients who desire a skin-tightening procedure prefer noninvasive skin tightening to invasive or surgical skin tightening [1,2].

To meet the demand of patients for noninvasive skin tightening, numerous devices have been developed. Laser and radiofrequency devices have been developed to resolve skin wrinkling and sagging [1-8]. Recently, micro-focused ultrasound (MFU) was developed as an effective noninvasive skin-tightening method. MFU is able to heat tissue greater than 60°C and produce a small thermal coagulation zone (<1 mm<sup>3</sup>) to reach the mid- to deep reticular layers of the dermis and subdermis while minimizing overlying papillary dermal and epidermal injury [9-11]. The delivery of MFU to a targeted zone in the superficial musculoaponeurotic system (SMAS) provokes immediate contracture of denatured collagen and the initiation of neocollagenesis and collagen remodeling [10,12]. This action of MFU provokes noninvasive skin tightening and lifting of sagging facial skin. Certain factors have limited its replacement of invasive surgical procedures, including a relative lack of efficacy, persistence, and reliability. The purpose of this study was to evaluate the efficacy and safety of MFU for noninvasive skin tightening and to determine how long the skin tightening can be maintained.

### METHODS

Between October 2013 and November 2014, 41 patients with sagging and laxity of the facial skin were treated

License (<http://creativecommons.org/licenses/by-nc/3.0/>) which permits unrestricted non-commercial use, distribution, and reproduction in any medium, provided the original work is properly cited. [www.e-aaps.org](http://www.e-aaps.org) This is an Open Access article distributed under the terms of the Creative Commons Attribution Non-Commercial License (<http://creativecommons.org/licenses/by-nc/4.0/>) which permits unrestricted non-commercial use, distribution, and reproduction in any medium, provided the original work is properly cited.

with MFU using 4-MHz, 4.5 mm and 7-MHz, 3.0 mm depth transducers (Ultraformer®, Classys Inc., Seoul, Korea). Treatment was performed following the manufacturer’s recommended protocol that called for 300 treatment lines. Patients with active systemic or local infections, local skin diseases that might alter wound healing, history of psychiatric illness, and soft tissue augmentation material were excluded from this study.

**Pretreatment preparation**

Five percent lidocaine, as a topical anesthetic ointment (EMLA, AstraZeneca, Sdertlje, Sweden), was applied to the face for 45 minutes before the procedure. The ointment was washed off with mild soap and water immediately before the procedure.

**Ultrasound exposure protocol**

The ultrasound gel was applied to the skin. The transducer was placed firmly on the targeted skin surface and pressed uniformly for coupling to the skin. Treatment exposure was initiated (4-MHz, 4.5 mm depth transducers; 0.9 J/mm<sup>2</sup> and 7-MHz, 3.0 mm depth transducers; 0.8 J/mm<sup>2</sup>), with a line of individual ultrasound pulses being delivered within approximately 2 seconds. Then, the transducer slid to the next location and was repositioned 3 to 5 mm laterally such that it was adjacent and parallel to the previous treatment line. Complete treatment of the face required 15 to 20 minutes.

**Post-treatment care**

The ultrasound gel was washed off. Patients experienced mild redness and swelling that could persist for several days. Patients were instructed to visit our hospital promptly if they encountered any other adverse effects.

**Table 1.** Patients Characteristics

Characteristic	Value
Sex (Female, Male)	37, 1
Mean Age (range)	46 (37-52)

**Outcome evaluation**

We evaluated the patients using an automatic skin diagnosis system(A-One Lite®, BOMTECH Electronics

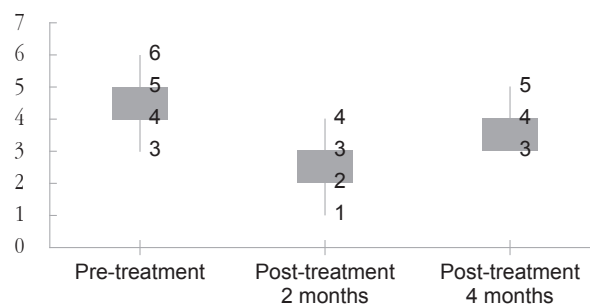
Co., Seoul, Korea) at pretreatment, and 2 and 4 months after treatment. The automatic skin diagnosis system evaluated skin laxity using a scanner. The sagging and laxity of the skin were graded from 1 to 6 using the system. A high skin grade score means that the sagging and laxity of the skin are severe. The clinician examined the skin for evidence of edema, erythema, hypopigmentation, and hyperpigmentation after treatment.

**Statistical analysis**

Statistical analyses were performed using SPSS version 20.0 (SPSS Inc., Chicago, IL, USA). The Friedman test was used to compare the grade scores of patients at pretreatment, and 2 and 4 months after treatment. A P value less than 0.05 was considered statistically significant.

**RESULTS**

All patients were treated using MFU and three patients were lost to follow-up for non-study related reasons. In our study, 38 patients (1 male and 37 female) were evaluated and ranged in age from 37 to 52 years (Table 1).



**Fig. 1.** Comparisons of skin grade scores at pre-treatment and 2 months post-treatment, pre-treatment and 4 months post-treatment 4 months, and 2 and 4 months post-treatment.

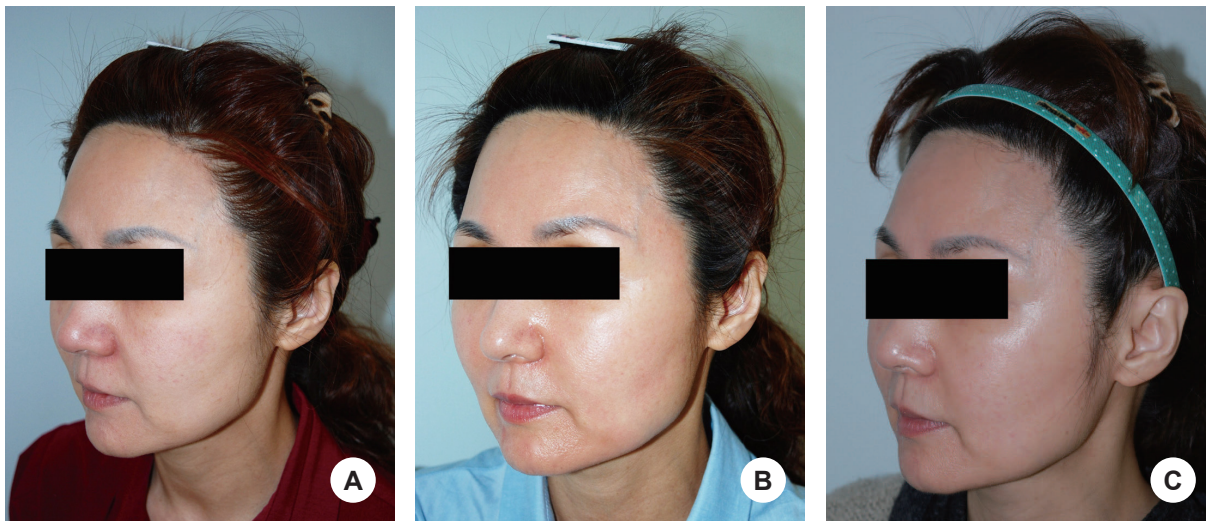**Table 2.** The skin grade score

Time	Pre-treatment (Median)	Post-treatment 2 months (Median)	Post-treatment 4 months (Median)	P-value*,†,‡
Skin grade score	5*,‡ (4-5)	3*,† (2-3)	3†,‡ (3-4)	< 0.01

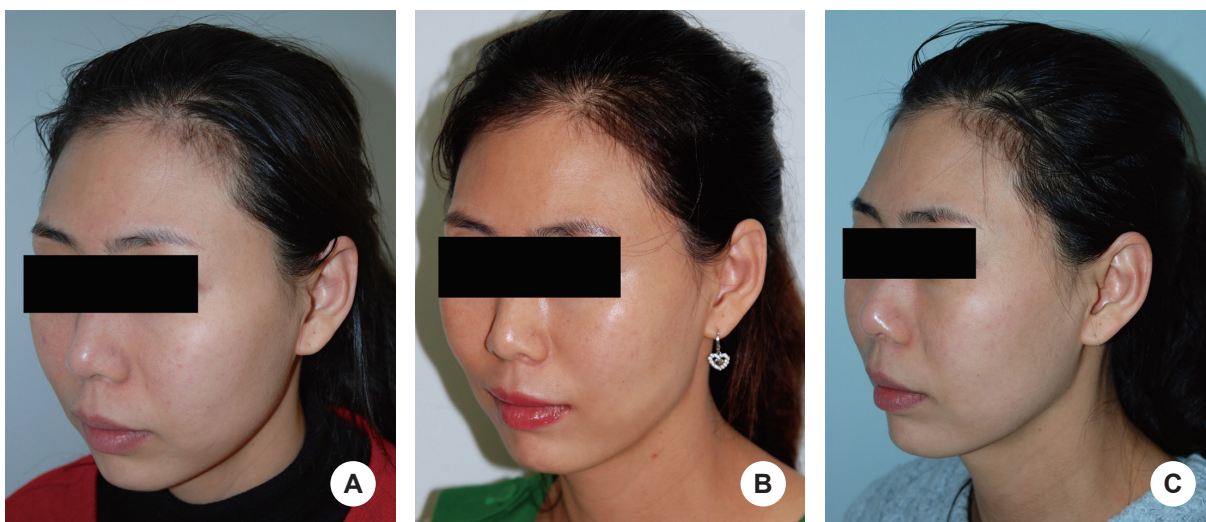
\*,†,‡P-value by Wilcoxon signed rank test.

Thirty-five patients immediately presented with slight erythema and edema after treatment, and three patients immediately presented with moderate erythema and edema after treatment. In all affected patients, both erythema and edema completely resolved by 2 days after treatment. Two patients presented with red linear striations of the cheek after treatment with the 3 mm transducer. They were treated using focal cooling without sequelae such as pigmentation and textural

abnormalities. Hypopigmentation, hyperpigmentation, ulceration, and erosion were not present in any patients. There were no adverse events, such as nerve or muscle dysfunction, severe pain, bruising, and bleeding. The median skin grade scores were 5 (4-5) at pretreatment, 3 (2-3) at 2 months post-treatment, and 3 (3-4) at 4 months post-treatment (Fig. 1 and Table 2). After comparing pre-treatment and 2 months post-treatment, pre-treatment and 4 months post-treatment,



**Fig. 2.** A 46-year-old female patient with moderate skin sagging and wrinkling. At pre-treatment, she was examined by the automatic skin diagnosis system and was given a skin grade score of 5 (A). At 2 months post-treatment, the skin grade score was 2 (B). At 4 months post-treatment, the skin grade score was 4 (C).



**Fig. 3.** A 38-year-old female patient with moderate skin sagging and wrinkling. At pre-treatment, she was examined by the automatic skin diagnosis system and was given a skin grade score of 4 (A). At 2 months post-treatment, the skin grade score was 2 (B). At 4 months post-treatment, the skin grade score was 3 (C).

and both 2 and 4 months post-treatment, there was a statistically significant difference in skin grade score ( $P < 0.01$ ) (Fig. 2 and 3).

## DISCUSSION

The SMAS consists of viscous, elastic fibers and extracellular matrix [10,13,14]. It is associated with specific facial muscles, such as the platysma, orbicularis oculi, and levator labii superioris. Collagen within SMAS decreases 6% every decade [10]. This decrease in collagen contributes to a prominent nasolabial fold, and hooding of the brow and jowl [10,15,16]. To minimize post-treatment adverse events, clinicians have developed various non-ablative skin-tightening procedures to induce collagen shrinkage and remodeling [3,6,17]. Furthermore, ultrasound is able to penetrate into the subdermis layer and SMAS, and induce thermal coagulation to avoid undesired post-treatment adverse events compared with carbon-dioxide laser resurfacing [17-19].

Ultrasound energy has characteristics that are suitable for skin lifting and tightening. First, it is believed that ultrasound energy can be transmitted into the deeper subcutaneous layer of the face or even the SMAS, and is the most effective method for skin lifting and tightening [13,14,20-23]. Second, both the epidermis and dermis can be protected from ultrasound energy during its transmission, reducing the risk of advertent cutaneous layers [1].

Ultrasound used in medicine is classified into two types. One is high-intensity focused ultrasound (HIFU) and the other is MFU. HIFU uses high energy and is mainly used for nonsurgical ablation of tumors. HIFU can also be used to ablate adipose tissue for body contouring [10]. MFU uses much lower energy to treat the superficial layer of the skin [9] and is able to elevate the local temperature higher than 60°C to cause collagen contracture [24]. When energy is targeted to discrete areas within dermal and subdermal tissues,

MFU induces discrete thermal coagulation zones while sparing adjacent non-target tissues [9,11,12,25]. In addition, the heat induces the denaturation and contraction of collagen fibers in the subcutaneous fat layer [26].

According to the results of our study, skin tightening at 2 and 4 months post-treatment was improved compared to pretreatment. However, skin tightening at 2 months post-treatment was better than at 4 months post-treatment, suggesting the efficacy of MFU gradually decreases treatment. Based on our results, we recommend that retreatment should be performed after 3 months for greater efficacy.

Our study had limitations. First, our study did not include patients who had severe skin sagging and wrinkling. We recommended the surgical face-lift procedure for these patients. Second, the post-treatment results were evaluated with an automatic skin diagnosis system, but the reliability of the system has not been established. Therefore, discrepancies may occur between the automatic skin diagnosis system and realistic skin conditions. Third, our study did not include any histologic evaluations. Fourth, the MFU device that we used in our study is not capable of clearly imaging the targeted facial anatomy. We cannot ensure proper acoustic coupling between the transducer and skin before the application of MFU energy. Despite these limitations, the results were evaluated objectively.

## CONCLUSION

This study suggests that the aging face, with wrinkling and sagging, can be improved using MFU, while minimizing injury to the epidermis and dermis. In addition, retreatment is recommended after 3 months to maintain the efficacy of the results.

## PATIENT CONSENT

Patients provided written consent for the use of their images.

## REFERENCES

1. Alam M, White LE, Martin N, et al. Ultrasound tightening of facial and neck skin: a rater-blinded prospective cohort study. *J Am Acad Dermatol* 2010;62:262-9.
2. Dover JS, Zelickson B. Results of a survey of 5,700 patient monopolar radiofrequency facial skin tightening treatments: assessment of a lowenergy multiple-pass technique leading to a clinical end point algorithm. *Dermatol Surg* 2007;33:900-7.
3. Fitzpatrick R, Geronemus R, Goldberg D, et al. Multicenter study of noninvasive radiofrequency for periorbital tissue tightening. *Lasers Surg Med* 2003;33:232-42.
4. Fitzpatrick RE, Goldman MP, Satur NM, et al. Pulsed carbon dioxide laser resurfacing of photo-aged facial skin. *Arch Dermatol* 1996;132: 395-402.
5. Goco PE, Stucker FJ. Subdermal carbon dioxide laser cutaneous contraction. *Arch Facial Plast Surg* 2002;4:37-40.
6. Kim KH, Geronemus RG. Nonablative laser and light therapies for skin rejuvenation. *Arch Facial Plast Surg* 2004;6:398-409.
7. Kirsch KM, Zelickson BD, Zachary CB, et al. Ultrastructure of collagen thermally denatured by microsecond domain pulsed carbon dioxide laser. *Arch Dermatol* 1998;134:1255-9.
8. Zelickson BD, Kist D, Bernstein E, et al. Histological and ultrastructural evaluation of the effects of a radiofrequency-based nonablative dermal remodeling device: a pilot study. *Arch Dermatol* 2004;140:204-9.
9. Fabi SG. Noninvasive skin tightening: focus on new ultrasound techniques. *Clin Cosmet Investig Dermatol* 2015;8:47-52.
10. Fabi SG, Goldman MP. Retrospective evaluation of micro-focused ultrasound for lifting and tightening the face and neck. *Dermatol Surg* 2014;40:569-75.
11. Laubach HJ, Makin IR, Barthe PG, et al. Intense focused ultrasound: evaluation of a new treatment modality for precise microcoagulation within the skin. *Dermatol Surg* 2008;34:727-34.
12. White WM, Makin IR, Barthe PG, et al. Selective creation of thermal injury zones in the superficial musculoaponeurotic system using intense ultrasound therapy: a new target for noninvasive facial rejuvenation. *Arch Facial Plast Surg* 2007;9:22-9.
13. Ghassemi A, Prescher A, Riediger D, et al. Anatomy of the SMAS revisited. *Aesthetic Plast Surg* 2003;27:258-64.
14. Har-Shai Y, Bodner SR, Egozy-Golan D, et al. Mechanical properties and microstructure of the superficial musculoaponeurotic system. *Plast Reconstr Surg* 1996;98:59-70.
15. Kikkawa DO, Lemke BN, Dortzbach RK. Relations of the superficial musculoaponeurotic system to the orbit and characterization of the orbitomalar ligament. *Ophthal Plast Reconstr Surg* 1996;12:77-88.
16. Psillakis JM, Rumley TO, Camargos A. Subperiosteal approach as an improved concept for correction of the aging face. *Plast Reconstr Surg* 1988;82:383-94.
17. Fabi SG, Massaki A, Eimpunth S, et al. Evaluation of microfocused ultrasound with visualization for lifting, tightening, and wrinkle reduction of the décolletage. *J Am Acad Dermatol* 2013;69:965-71.
18. Alster TS, Tanzi E. Improvement of neck and cheek laxity with a nonablative radiofrequency device: a lifting experience. *Dermatol Surg* 2004; 30:503-7.
19. Kennedy JE, Ter Haar GR, Cranston D. High intensity focused ultrasound: surgery of the future? *Br J Radiol* 2003;76:590-9.
20. Har-Shai Y, Sela E, Rubinstien I, et al. Computerized morphometric quantitation of elastin and collagen in SMAS and facial skin and the possible role of fat cells in SMAS viscoelastic properties. *Plast Reconstr Surg* 1998;102:2466-70.
21. Mendelson BC. Surgery of the superficial musculoaponeurotic system: principles of release, vectors, and fixation. *Plast Reconstr Surg* 2001; 107:1545-52.
22. Mitz V, Peyronie M. The superficial musculo-aponeurotic system (SMAS) in the parotid and cheek area. *Plast Reconstr Surg* 1976;58:80-8.
23. Thaller SR, Kim S, Patterson H, et al. The submuscular aponeurotic system (SMAS): a histologic and comparative anatomy evaluation. *Plast Reconstr Surg* 1990;86:690-6.
24. Hayashi K, Thabit G, 3rd, Massa KL, et al. The effect of thermal heating on the length and histologic properties of the glenohumeral joint capsule. *Am J Sports Med* 1997;25:107-12.
25. Gliklich RE, White WM, Slayton MH, et al. Clinical pilot study of intense ultrasound therapy to deep dermal facial skin and subcutaneous tissues. *Arch Facial Plast Surg* 2007;9:88-95.
26. Ferraro GA, De Francesco F, Nicoletti G, et al. Histologic effects of external ultrasound-assisted lipectomy on adipose tissue. *Aesthetic Plast Surg* 2008;32:111-5.